

Management of the malignant colorectal polyp: ACPGBI position statement¹

J. G. Williams*, **R. D. Pullan†**, **J. Hill‡**, **P. G. Horgan§**, **E. Salmo¶**, **G. N. Buchanan****,
S. Rasheed††, **S. G. McGee‡‡** and **N. Haboubi§§**

*Royal Wolverhampton Hospitals NHS Trust, Wolverhampton, UK, †Torbay Hospital, Torquay, UK, ‡Department of General Surgery, Manchester Royal Infirmary, Manchester, UK, §Royal Infirmary, Glasgow, UK, ¶Department of Histopathology, Royal Bolton NHS Foundation Trust, Bolton, UK, **Imperial College Healthcare NHS Trust, Charing Cross Hospital, London, UK, ††The Royal Marsden Hospital, London, UK, ‡‡Salisbury NHS Foundation Trust, Salisbury, UK and §§Department of Histopathology, University Hospital of South Manchester, Manchester, UK

Introduction

A colorectal polyp is an abnormal protrusion of the mucosa into the bowel lumen that is classified by histopathological examination (Fig. 1). Adenomas are a common finding during colonoscopy in symptomatic patients and in asymptomatic individuals undergoing screening. It is estimated that the prevalence of large-bowel adenoma is 21–28% in 50–59-year-old subjects, increasing to 40–45% in 60–69-year-old subjects and rising further to 53–58% in people over the age of 70 [1]. Adenomas are important as they are the precursor lesion of most colorectal cancers arising through the adenoma–carcinoma sequence [2]. This association is supported by epidemiological, clinical and molecular research [3]. Whilst most polyps removed are small, it is well recognized that the risk of malignant transformation increases with increasing polyp size. There is compelling evidence that removing adenomas from the colon substantially reduces the risk of a patient developing colorectal cancer [4].

The term ‘malignant polyp’ refers to an adenoma that appears benign macroscopically but in which there is invasion through the muscularis mucosae into the submucosa. Such a focus of carcinoma is detected on histological examination. A malignant polyp is therefore an early carcinoma. It accounts for 0.75–5.6% [5–9] of large-bowel polyps removed in general diagnostic colonoscopy practice. The wide discrepancy is explained by differences in the study populations, being lower where all polyps removed are histologically assessed and higher in series that only include larger polyps. In the Nottingham Bowel Cancer Screening Trial, 1466 patients underwent colonoscopy because of a positive faecal occult blood-test result. Of these, 710 (48%) were found to have an adenoma and a further 73 (5%) had an adenoma containing a focus of cancer [10]. A similar

incidence of malignant polyps has been found in the National Bowel Cancer Screening Programme. Of the first 1-million individuals screened, just over 17 000 had a positive faecal occult blood-test result. Of these, 1574 (9%) had cancer of which 155 (10%) were malignant polyps [11]. In recent years, greater use of diagnostic colonoscopy has been accompanied by a rise in the number of malignant polyps removed endoscopically [12].

The management of a malignant polyp following endoscopic removal is difficult because the possibility of residual malignant cells within the bowel wall or positive regional lymph nodes varies from patient to patient, depending on a number of prognostic factors. The evidence base for management of these lesions is poor and is mostly based on data from symptomatic patients [6,13,14]. Advising patients on the course of action after removal is difficult. It includes surveillance only, where the risk of residual disease is deemed to be low, or major surgical resection for those with a higher risk. However, the level of risk is often difficult to calculate. Furthermore, the presence of comorbidity and the site of the lesion should also be considered when discussing further management with the patient.

This position statement deals with a number of matters relating to the management of patients with a malignant polyp. It is divided into four sections. The first section considers colonoscopy and includes a discussion of endoscopic techniques for the removal of larger adenomas, which are more likely to be malignant. The influence of polypectomy technique on histopathological assessment and the regimens for postresection endoscopic surveillance are discussed. The second section reviews the histopathology of adenomas and polypoid carcinomas and considers important prognostic indicators. The third section deals with how the prognostic indicators influence the risk of residual cancer in the bowel wall or lymph nodes to estimate the likelihood of recurrence if no further treatment is undertaken. The traditional advice for a ‘high-risk’ adenoma was to advise a radical ‘cancer’ segmental colectomy,

Correspondence to: J. Graham Williams MCh, FRCS, BSc, Department of Colorectal Surgery, New Cross Hospital, Wolverhampton WV10 0QP, UK. E-mail: graham.williams4@nhs.net

¹This Position Statement is based on a symposium at the Association of Coloproctology Annual Scientific Meeting, Dublin, 2 July 2012.

including the lympho-vascular pedicle. The fourth section discusses the balance of the risk of morbidity and mortality following endoscopic resection against the risk of recurrence and how this risk is communicated to the patient. Finally, the role of endoscopic and radiological imaging in the assessment and follow up of malignant polyps is considered, particularly where radical surgery is not performed. This also includes a discussion of the optimal follow-up protocol.

Method

Searches of the Cochrane Database, PubMed, MEDLINE and Embase were performed using keywords relevant to each section of the position statement. They were mostly limited to English-language articles. Additional publications were retrieved from references cited in articles identified from the primary search. All evidence was classified according to an accepted hierarchy of evidence, and recommendations were graded from A to C on the basis of the level of associated evidence and/or noted as Good Practice and/or part of the National Institutes of Clinical Excellence/ Scottish Intercollegiate Guidelines Network (NICE/SIGN) recommendation or Rapid Technology Appraisal (Table 1)[15].

A: Role of colonoscopy in the management of malignant polyps

Modern endoscopic practice is safe, thorough and offers extensive opportunities for identification, diagnosis

and definitive management of most benign colorectal neoplasms. A small proportion of these will be early cancers, and the diffusion of colorectal cancer screening has led to more of these being discovered [16]. The purpose of this section is to illustrate how, with proper location and characterization of colorectal neoplasms, malignant lesions can be detected and treated optimally by endoscopy alone when appropriate. This should reduce the number of 'surprise' malignant polyps and the clinical dilemmas they cause. It will reduce the necessity for surgery for inadequately treated polyps. Surgery can then be targeted on lesions with a high risk of local recurrence, lymph node metastasis and colorectal cancer death [17].

Optimal colonoscopic performance to detect neoplasia

The prerequisite for colonoscopy is a safe, complete examination of the entire colon and rectum. Great strides have been made in the completeness and accuracy of UK colonoscopy since the survey carried out by Bowles *et al.* [18] showed variable performance and unsatisfactory caecal intubation and complication rates and low levels of colonoscopy training. Re-audit following investment in training, accreditation and setting of quality assurance standards has demonstrated great improvements in examination quality, diagnostic accuracy and the safety of colonoscopy in the UK [19].

Quality colonoscopy optimizes the chance of finding pathology. White light examination (WLE) alone is

Table 1 Levels of evidence and grades of recommendation.

Level of evidence		Grade of evidence	
I	Evidence obtained from a single randomized controlled trial or from a systematic review or meta-analysis of randomized controlled trials	A	Evidence of Type I or consistent findings, from multiple studies, of Type IIa, Type IIb or Type III
IIa	Evidence obtained from at least one well-designed controlled study without randomization	B	Evidence of Type IIa, Type IIb or Type III and generally consistent findings
IIb	Evidence obtained from at least one other well-designed quasi-experimental study	C	Evidence of Type, IIa Type IIb or Type III, but inconsistent findings
III	Evidence obtained from well-designed nonexperimental descriptive studies, such as comparative studies, correlation studies and case studies	D	Little or no systematic evidence
IV	Evidence obtained from expert committee reports or opinions and/or clinical experiences of respected authorities, case reports	GP	Recommended good practice based on the clinical experience of the expert group and other professionals*

Adapted from Eccles M, Mason J and NHS Executive. Clinical Guidelines: Using Clinical Guidelines to Improve Patient Care within the NHS. London: 1996.

*Previous experience and the literature in this area suggest that given the relative lack of evidence for many health-care procedures, expert opinion and professional consensus are likely to be an important part of this process.

usually sufficient to identify colonic abnormalities, but tandem colonoscopy shows that this may miss 22% of all adenomas and 2.1% of adenomas over 1 cm in diameter [20]. Most malignant polyps are larger pedunculated or protruding sessile lesions. These are usually easy to see. An important minority of neoplasms is not truly polypoid, but flat or even depressed. These are harder to spot but carry a much greater risk of malignancy. The challenge is to find these lesions.

Good bowel preparation, meticulous mucosal washing, insufflation and careful inspection are critical [21]. The flexures and inner angles of colonic folds are sites where there is a higher risk of lesions being missed and they require more careful inspection. Modern endoscopes have better bending sections, allowing retroflexion in the caecum and rectum to view the caecum beyond the ileocaecal valve and distal rectum. Right-sided colonic lesions are easier to miss because they tend to be flatter. Missed right-sided lesions may explain why colonoscopic screening has failed to make the hoped-for impact on the detection of right-sided colonic cancer [22]. Patient repositioning during the examination, with the inspected flexure uppermost to open up collapsed areas, increases luminal distension [23] and adenoma detection [24]. The time spent inspecting the mucosa (the withdrawal time) should be sufficient to allow a thorough mucosal view. The influence of a careful examination technique is highly significant for detection. Barclay *et al.* [25] found that colonoscopists who took longer than 6 min in the withdrawal and inspection phase had a higher detection rate for any neoplasm (28.3% *vs* 11.8%) and for advanced neoplasms (6.4% *vs* 2.6%) than those with a shorter inspection time. The adenoma detection rate (ADR) is a surrogate marker of the quality of colonoscopy and can therefore be used as a comparative measure in studies. Kaminski *et al.* [26] used the Polish bowel cancer screening data set to validate ADR as a quality indicator. They showed that an individual endoscopist's ADR is associated with the subsequent interval cancer risk, with a lower ADR predicting significantly higher interval cancer risk.

Findings

The quality of colonoscopy can be monitored using the adenoma detection rate and is enhanced by excellent preparation and meticulous technique. During withdrawal, inspection for more than 6 min and patient repositioning increases the adenoma detection rate, which is a reproducible quality marker (Level IIa).

Recommendations

Attention to preparation and endoscopic technique, especially the inspection (withdrawal) phase, will increase the

quality of the examination and detection of pathology (Grade B).

Techniques to improve polyp detection

Polyps may be missed, either because they are subtle by being small, flat or depressed, or because they hide behind folds and flexures.

Dye spray chromoendoscopy

Dye spray chromoendoscopy uses contrast reactive dyes, such as indigocarmine, to enhance mucosal features. At concentrations of 0.1–0.8%, indigocarmine fills cavities, pits and grooves in the mucosa and even flat, small polyps will be detected. Chromoendoscopy has been shown to increase the ADR but it is awkward and time consuming for use in routine practice. Other vital or absorptive dyes, such as crystal violet or methylene blue, are actively absorbed into the intestinal crypts, where they stain the convex portions but not the grooves. Very detailed magnification views are possible, but these dyes are slow to absorb and messy to use. A Cochrane collaborative review comparing white light and chromoscopic detection of colorectal neoplasia showed significantly enhanced detection of neoplasms using chromoendoscopy [27,28]. Most of the extra adenomas seen were diminutive, and more patients were found to have multiple polyps. Histology of these extra adenomas showed mostly low-grade dysplasia: this, plus the time to perform dye spray, has prevented pancolonoscopic chromoscopy from becoming routine. Selective application of dye spray to areas of subtle mucosal change is valuable and can detect a higher number of neoplasms and help differentiate neoplastic from non-neoplastic lesions [29]. Chromoendoscopy has a valuable place in detecting dysplasia in ulcerative colitis surveillance [30].

Findings

Dye spray chromoendoscopy enhances detection of colonic pathology, differentiation of neoplastic and non-neoplastic lesions and of dysplasia in inflammatory bowel disease (Level I).

Recommendations

Endoscopists should selectively use dye spray chromoendoscopy as it enhances detection and differentiation of colonic pathology (Grade A).

Optical and processor-based technologies

Optical and processor-based technologies are near-instant methods to examine the mucosa to delineate polyps. There are no clear data to indicate that these methods increase the adenoma-detection rate but they

have proven ability to characterize polyps once found [31]. Narrow band imaging (NBI; marketed by Olympus), multiband imaging (MBI) (marketed as FICE – flexible spectral imaging colour enhancement; Fujinon) and i-scan (Pentax) manipulate the wavelengths of light used to examine the mucosa. NBI uses a real-time optical filter to select two or three restricted wavelengths of light to emphasize the mucosal microvasculature and identify vascular alterations associated with pathological conditions. FICE and i-scan are postprocessor technologies that recreate the image as per the desired wavelengths to enhance mucosal surface patterns. Autofluorescence imaging (AFI; marketed by Olympus) uses tissue-component responses to specific short and ultraviolet wavelengths, the characteristics of which are different in neoplasms. Because these technologies are based on different endoscope platforms, UK endoscopists rarely have a choice of technology.

There is doubt whether NBI, FICE, i-scan or AFI improve the ADRs compared with good white light colonoscopy (WLC) in average-risk patients. Rex and Helbig [32] found no additional benefit with NBI compared with an expert using WLE. Adler *et al.* [33] found a nonsignificant trend for NBI for adenoma detection. In higher-risk patients under surveillance for hereditary nonpolyposis colorectal cancer (HNPCC), East *et al.* [34] showed significantly improved adenoma detection – typically subtle flat adenomas. A recent Cochrane review found no evidence that NBI is better than high-definition WLC at detecting adenomas, but NBI was better than standard-definition WLC and equal to high-definition WLC [35]. A study by Kuiper *et al.* [36] compared adenoma-detection rates and polyp characterization using high-definition white light, AFI and NBI. There was no improvement in detection using these technologies over WLE but they proved sensitive and specific in differentiating neoplastic and non-neoplastic lesions. It is this property – and the speed of switching mode – that makes these systems valuable. Training and practice are critical for these techniques to be clinically valuable in everyday use; training programmes are being developed [37].

Findings

A careful, expert white light examination of the colon can be augmented by selective or targeted chromoscopy and/or optical enhancement to examine suspicious areas (Level I).

Recommendations

Techniques that enhance surface and vascular patterns of colonic lesions should be used in routine practice. Endoscopists should learn to interpret these imaging methods (Grade B).

Cap colonoscopy

Cap colonoscopy – fitting a standard endoscope with a disposable hood or cap, can be used to improve exposure of hidden mucosa. The capped endoscope can be flexed against haustral folds, flattening them. A better view of the mucosa beyond the fold can then be obtained. Westwood *et al.* [38] recently reviewed published experience with this technique and found an increase in polyp detection and caecal intubation rates.

Prediction of histological features of polyps from endoscopic appearance

As yet there is no reliable way to accurately predict malignant change in a polyp, but there are features of polyp size, shape, consistency, surface and vascularity that should alert the endoscopist to possible malignancy. Combining sophisticated imaging modalities may eventually provide an ‘optical biopsy’ [39]. Knowledge and accurate use of these descriptive methods allows malignant risk stratification.

Polyp size

The Erlangen Group [40] examined 11 188 adenomatous polyps in a European series from 1978 to 1993. Using multivariate analysis they related malignant risk to a number of features – both within the patients themselves (age and sex) and related to the multiplicity, site, size and histological type of polyps. Polyps < 5 mm in diameter carry negligible risk of malignancy, whereas those with a diameter of more than 25 mm carry a considerable risk (Table 2).

There are problems with estimating size *in vivo*. A useful guide is that an open standard biopsy forcep width is 8 mm, while a closed forcep width is 2.5 mm. Endoscopists must practise taking such measurements.

Polyp site

The site of a polyp within the colon is also a risk factor where proximal colonic polyps are, size for size, at greater risk of containing malignancy [41] (Table 3). The malignant risk for adenomas in the right colon (proximal to the splenic flexure) was higher than that for similar-size left-sided or rectal polyps. Increasing use of positional imaging technology allows more reliable description of lesion position in the colon – which can otherwise be inaccurate.

Polyp morphology

Simple pattern recognition and experience are important. Malignancy is more likely when the contour is

Table 2 Rate of invasive carcinoma as a function of adenoma size.

Size of adenoma (mm)	Proportion of polyps (%)	Carcinoma in polyp (%)
< 5	44.9	0
6–15	31.5	2.2
16–25	9.4	18.7
26–35	4.6	42.7
> 35	9.6	75.8
All	100	11.7

Data from Nusko *et al.* [40] relating polyp size to histological diagnosis after polyp removal in a database of 11 188 polyps.

Table 3 Rate of invasive cancer as a function of adenoma site.

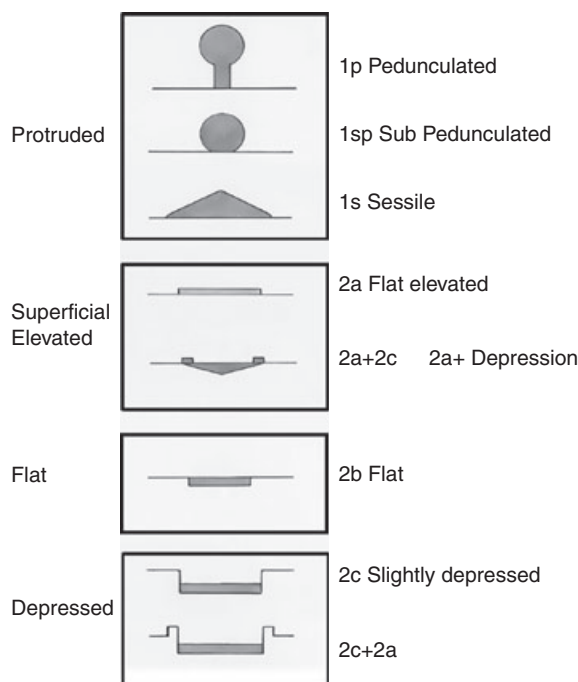
Adenoma site	Proportion of polyps (%)	Cancer (%)
Right colon	19.3	17.9
Left colon	45.6	13.8
Rectum	34.9	32.9

Data from Nusko *et al.* [40], relating the proportion of polyps found in the right colon (caecum to splenic flexure), left colon and rectum.

irregular, when there is ulceration or when the consistency of the polyp (when probed gently) is hard or when the stalk broadens [42]. These classical signs are not always evident, and more sophisticated classifications have been developed.

Japanese endoscopists recognized that many gastrointestinal neoplasms were not classically protuberant. This grew from their work on early gastric cancers. In the colorectum too they found significant numbers of flat, pancake-shaped, or even depressed, neoplastic lesions. The Japanese Research Society for Cancer of the Colon and Rectum developed a morphological classification [43] closely associated with Kudo [44]. The Paris collaborative meeting in 2002 modified this as an international consensus and published the Paris Classification [45,46]. The two systems differ only slightly. Figure 1 shows the Paris superficial or 0 type lesion (confined to mucosa and submucosa) classification. These systems allow classification for comparative and descriptive purposes and further allow prediction of polyp histology and direct appropriate therapy.

- 1 Polypoidal types consist of pedunculated (type 0-Ip) and sessile (0-Is) morphologies.
- 2 Nonpolypoidal or flat types consist of flat or slightly elevated (type 0-2A), completely flat (0-2B) and slightly depressed but not ulcerated (0-IIc) morphologies.

**Figure 1** Paris consensus classification of the morphological appearance of colonic polyps based on that of Kudo [45,46].

- 3 Truly excavated or ulcerated superficial lesions (type 0-III) are never seen in the colon.

Lesions called 'flat' are rarely completely flat. The Paris Classification defines 'flat' as < 2.5 mm in height above the mucosa, which is the width of closed, standard endoscopic biopsy forceps. The category not specifically classified in the Paris Classification is the lateral spreading tumour (LST); in Europe and USA these are carpet adenomas. LSTs are flat adenomas larger than 10 mm in diameter that extend circumferentially and laterally rather than vertically. They may have a granular (LST-G) or a nongranular (LST-NG) surface. Nodules and depressed areas are seen within these lesions. They have a malignant potential that is not predicted solely by size but rather by the presence of nodules or depressed areas within them. The cancer risk in LST varies between 7% (LST-G) and 14% (LST-NG): the Paris Classification defines these as type 0-IIa [47]. Table 4 shows the frequency of lesions classified by the Paris system related to both their size and the rate of submucosal invasion. The data are from Kudo, using the Paris system and include colon and rectal lesions [45].

Classical protuberant lesions (0-Ip and 0-Is) are common, and size influences invasive risk: lesions of 5 mm or less are associated with negligible risk, but for lesions over 20 mm the risk of malignancy is high. Recognition of depression (type 0-IIc) in colorectal lesions is critical

Table 4 Polyp morphology, according to the Paris Classification, related to both size and risk of submucosal invasion.

Lesion type	Polyp size				
	≤ 5 mm	6–10 mm	11–15 mm	16–20 mm	≥ 21 mm
Type 0-I (1p + 1s)	0/5400 (0)	49/4045 (1.2)	80/1002 (8)	58/330 (17)	56/187 (30)
Type 0-IIa,b (IIa + IIb)	2/6214 (< 0.1)	2/1015 (0.2)	9/493 (1.8)	17/165 (10)	53/235 (23)
Type 0-IIc (all IIc)	17/236 (7)	58/132 (44)	42/63 (67)	18/20 (90)	13/15 (87)
Type 0-III	0	0	0	0	0
Total	19/11 850 (< 0.2)	109/5192 (2)	131/1558 (8)	93/1523 (18)	122/437 (28)

Values are given as *n*/total *n* (%). Paris endoscopic classification of superficial colorectal neoplasms, relating submucosal invasion to polyp morphology and size. This table, redrawn from Kudo's submission to the Paris Workshop 2003, [45] shows the proportion (numbers and percentages) of invasion into the submucosa, with reference to the major macroscopic categories within Type 0 and to the diameter of the lesion (in five groups). Data were obtained from an endoscopy series with pathology confirmation (19 560 lesions in the period April 1985–April 2003) in the Red Cross Hospital in Akita and Showa Northern Hospital in Yokohama.

as this is often associated with invasive cancer, even when the lesion is small (< 10 mm). These true depressed lesions are rare but grow rapidly, become advanced at an early stage of the evolution of their growth and are seldom suitable for endoscopic resection. Initial clues are irregularities in mucosal appearances such as 'pinkness, minute depressions and/or haemorrhagic spots' [44]. Because they are subtle, dye spray chromoendoscopy with indigocarmine is invaluable to demarcate them from background innominate grooves and delineates the surface, edge and any areas of depression. The colonoscopy technologies NBI and FICE perform similar functions. Saitoh *et al.* [48] combined chromoendoscopy with indigocarmine plus magnification of the area – a refinement not widely available in the UK. Polyps with more submucosal invasion – sm2 and sm3 – tended to have an expansive look, deeper depression with irregularity of the depressed surface and two or more converging folds. Such descriptions are subtle and, whilst in expert hands are highly predictive of invasion (91% sensitivity), they are difficult to translate into standard practice.

For a time there was doubt that flat polyps occurred in western populations because they were not being reported. It is now clear they do occur and are being detected. The Leeds group analysed a series of 1000 consecutive colonoscopies and found 321 adenomas [49]. Amongst these were a substantial number of flat polyps and a small number of true depressed lesions with significant malignant potential. Table 5 is redrawn from their data and shows, in a snapshot from a single (tertiary) centre, that not only do flat and depressed polyps exist but also that they can be detected in a UK population, and it highlights the small, but appreciable, risk of early cancer in polyps < 1 cm in diameter, as well as the greater risk with flat lesions of more than 1 cm in diameter. Depressed lesions are rare but frequently invasive. Suzuki *et al.* [50] reported data from

Table 5 Flat and depressed polyps in a UK population (Rembacken *et al.* [49]).

Appearance	Proportion of lesions with early cancer [<i>n</i> /total <i>n</i> (%)]	Overall mean size (mm)
Polyps < 10 mm	9/154 (6)	5.7
Polyps ≥ 10 mm	8/50 (16)	15.8
Flat lesions < 10 mm	3/70 (4)	5.1
Flat lesions ≥ 10 mm	14/49 (29)	20.6
All depressed lesions	3/4 (75)	9.0

St Mark's Hospital in London where 10% of cancers found by colonoscopy were of flat configuration and small (only 8–15 mm in diameter). The English Bowel Cancer Screening Programme requires all polyps to be classified by an endoscopist using the Paris system.

Findings

Site, size and polyp morphology all influence assessment of malignancy in a lesion. The Paris Classification is both descriptive and predictive (Grade III).

Recommendations

Endoscopists should estimate size of polyps and use the Paris Classification to achieve the best prediction of malignancy (Level A).

Surface pit pattern endoscopic diagnosis of colorectal polyps

Detailed inspection of the surface of polyps can further predict histology. Chromoendoscopy using indigocarmine, together with magnifying colonoscopy can diagnose flat or depressed lesions and identify the pit pattern of polyps that predict underlying pathology. The Kudo Classification of pit patterns is shown diagrammatically in Figs. 2 [44,51].








Type	Characteristics	Close up	Pit size (mm)	Interpretation
I	Round, normal		0.07+/-0.02	Normal
II	Asteroid		0.09 ±0.02	Hyperplastic
III _S	Tubular or round pit smaller than normal pit (type I)		0.003 ±0.01	Neoplastic Tubular Adenoma
III _L	Tubular or round pit larger than normal pit (type I)		0.22 ±0.08	Neoplastic Tubular Adenoma
IV	Dendritic/gyrus brain-like		0.93 +/-0.32	Neoplastic Tubulovillous or villous
Vi	Irregular arrangement (sizes of III _S , III _L , IV type pits)		NA	Neoplastic High grade or invasive
Vn	Loss or decrease of pits with amorphous structure (Non-structural)			

Figure 2 Kudo classification of polyp pit patterns seen endoscopically with dye spray [44,51].

Table 6 Pit patterns and histology of lesions (April 2001–June 2005).

Pit pattern	Adenoma (dysplasia)		Submucosal cancer	Total
	Low grade	High grade		
IIIL	2714 (83.3)	546 (16.7)	0	3260
IV	400 (51.1)	364 (46.5)	19	783
III _S	29 (55.5)	22 (42.3)	1	52
Vi	35	165 (59.1)	79 (28.3)	279
Vn	0	8 (9.9)	73 (90.1)	81
Total	3178	1105	172	4455

Values are given as *n* or *n* (%). Redrawn from Kashida and Kudo [52] showing the proportion of polyps bearing particular pit patterns and the subsequent histology associated with that type.

Pit pattern Types I and II are non-neoplastic (normal or hyperplastic mucosa). Proximal hyperplastic polyps can belong to the serrated adenoma group and should be treated accordingly. Pit patterns III_S (small), III_L (large) and IV (gyriform) are most likely to be benign adenomas with a low risk of submucosal invasion.

Type V pit patterns indicate a high risk for invasion into at least the submucosa. The type-V pit pattern can further be divided into Vn (with pits devoid of structure (nonstructural)) and Vi (where pits are irregular). This subclassification is appreciated only with magnifying chromoendoscopy. Pit pattern Vi (irregular) may be on the surface of a benign lesion but submucosal invasion

can also occur. Vn has the highest likelihood of malignancy.

Using this classification, Kashida and Kudo [52] related pit pattern (seen with magnifying chromoendoscopy) to final histology of polyps. Table 6 summarizes their findings. The ability to identify pit patterns enables the endoscopist to predict malignant change within a polyp and select appropriate therapy. Kiesslich *et al.* [29] used a mixture of magnifying and nonmagnifying colonoscopy with chromoendoscopy to differentiate non-neoplastic and neoplastic lesions with 90% sensitivity and specificity – so it is not always necessary to use magnification. Pit pattern familiarity requires training and practise.

Narrow band imaging

Mucosal vascular pattern intensity and mucosal pattern assessment with NBI allows diagnostic differentiation of non-neoplastic polyps from neoplastic polyps and will detect malignant change [53]. With magnification, NBI provides detailed observation of the microcapillary architecture – the meshed capillary pattern. Disorganization of this pattern indicates dysplasia. Sano has defined microcapillary pattern types I to III, where type III shows malignant change. In the Sano-Emura Classification, type III is subdivided into types IIIA (intramucosal carcinoma and superficial submucosal carcinoma) and IIIB, with deep submucosal invasive cancer [54,55]. Detailed classification requires both magnification and considerable experience. Many endoscopists use NBI to

identify a neoplastic lesion and then chromendoscopic dye spray to characterize the pit pattern rather than rely on the NBI-defined microcapillary structure. East *et al.* [34] have demonstrated the value of NBI with magnification in defining neoplasia in diminutive polyps, high-risk groups and in chronic ulcerative colitis.

Whether NBI without magnification can be as predictive as the Sano-Emura-magnified NBI system remains to be shown. However, many UK endoscopists do not have ready access to magnifying colonoscopes.

Flexible spectral imaging colour enhancement

FICE is available with modern Fujinon colonoscopes and by detecting surface patterns can offer differentiation of polyp types. A predictive classification is now available and, in a study by Yoshida *et al.* [56], FICE was shown to offer similar discrimination to NBI when using magnification. Perhaps more importantly, a subsequent paper showed that FICE could discriminate neoplastic and non-neoplastic polyps without magnification [57]. Longcroft-Wheaton *et al.* [58] compared FICE with indigo carmine chromoscopy in small polyps and showed both modalities to have good specificity and sensitivity to discriminate neoplasia and non-neoplasia.

Other modalities

Other methods of surface and lesion examination, as well as endoscopic staging, are currently research tools or not currently sufficiently sensitive or specific to be widely recommended. Colonic endoscopic ultrasonography falls into this category, in contrast with endorectal ultrasonography, which is a routine tool in neoplastic assessment, particularly in conjunction with transrectal endoscopic microsurgery (see later). Optical coherence tomography and confocal laser endoscopy (CLE) are being evaluated [39]. A recent review and meta-analysis of CLE suggests that this modality offers comparable diagnostic accuracy to colonoscopic histopathology in colorectal neoplasia [59]. This offers the possibility of *in vivo* real-time optical biopsy in the colorectum. I-Scan is a new modality launched by Pentax (Hoya Corporation, Japan) to enhance lesions difficult to visualize by WLE. There is, as yet, little literature on its value in colorectal neoplastic characterization of malignant change [60].

Nonlifting sign (of Uno)

Simply injecting saline or any other fluid beneath a polyp can demonstrate if there is submucosal tethering consistent with invasion [61]. A lesion failing to lift relative to the surrounding mucosa indicates that simple snaring or endoscopic resection will not be adequate to clear the lesion. Ishiguro *et al.* [62], in a small group of patients

found nonlifting to correlate with sm3 invasion – early cancers that lifted were all sm1 or sm2 (i.e. tumour invasion of the upper third and of the middle third, respectively, of the submucosa). However, Kobayashi *et al.* [63] used a larger, multicentre design with either glycerol or saline as the lift agent and compared this with endoscopic evaluation. They found the nonlifting sign to offer lower sensitivity and accuracy compared with endoscopic evaluation for invasion depth (61.5 *vs* 84.6% and 94.8 *vs* 97.4%). They suggested that a nonlifting lesion will be technically difficult to resect and its depth of invasion more difficult to predict. A final feature of the nonlifting sign is that submucosal injection makes a further attempt at endoscopic removal, at a later date, more difficult by causing fibrosis. Therefore, submucosal injection should be avoided as a diagnostic test before referral to a tertiary centre for therapy, for example, as it makes success less likely [64].

Findings

Correct characterization of polyp size, morphology and surface pit pattern can predict histopathology of the lesion and allow estimation of the risk of malignant change and depth of invasion. The nonlifting sign predicts deeper submucosal invasion (Level I).

Recommendations

All colonoscopists should be familiar with and use the Paris morphological system. Surface enhancement by chromoendoscopy and either NBI or FICE are recommended to assess lesions being considered for advanced polypectomy techniques (Grade A).

Summary of polyp features favouring malignant change

- 1 Larger and/or flatter polyps.
- 2 Polyps with ulceration, an irregular contour or firmness.
- 3 Hard consistency and broadening of stalk.
- 4 Paris Type 0-IIc.
- 5 Kudo pit pattern type V (especially nonstructural).
- 6 Lateral spreading tumour – nongranular or a nodule in a granular type.
- 7 Nonlifting sign present.

Techniques of polypectomy

Any endoscopist's decision to perform polypectomy must be informed by features of the polyp, their own skill and experience and that of the team with whom they are working. They should ask four questions:

- 1 Can the lesion found be removed endoscopically?
- 2 Should it be removed endoscopically?

3 Can I remove it endoscopically?

4 Can I remove it all in one session or not?

There is no harm in deferring treatment for discussion with colleagues. It is a duty to ensure that optimal treatment is employed – and referral to an appropriate endoscopist, when necessary, is part of this duty of care. Good-quality photographs and/or video with dye spray or optical-enhancement techniques are essential for these discussions, so an appropriately skilled endoscopist can treat the patient or refer for surgery. Networks of experts are becoming established in the UK for such discussions (Dolwani personal communication; Sylvester and Bhandari personal communication) and have proved successful in the USA [65] and in Australia [66]. There are a variety of techniques and these are tailored to the type of polyp seen. The goal should always be, where possible, an *en-bloc* excision of the lesion in one session.

Snare polypectomy

Standard snare polypectomy is the mainstay of polyp management because the majority of lesions are protuberant. Polyp size, position and access can make this very taxing. When malignancy is suspected within a pedunculated polyp the snare should be placed closer to the bowel wall, to optimize resection margin. If the histology and margin are favourable, snare polypectomy will be curative [67]. Pretreatment to broad stalks in large polyps may be necessary and a variety of techniques are available, including adrenaline injection, clip application and haemostatic loops. Sessile polyps may be treated with snare polypectomy alone with success provided that adequate margins are achieved [68] but submucosal injection to enhance margin resection is now routine.

Most authors consider polypectomy of pedunculated malignant polyps technically satisfactory if the margin from the invasive component to diathermy burn is 2 mm or more (see later). It offers the lowest rate of local recurrence and metastases [69].

Endoscopic mucosal resection

[Synonyms: lift and snare polypectomy, submucosal injection polypectomy, lift and cut mucosal resection or (in Japan) strip biopsy.]

Raising a submucosal cushion with fluid to lift the mucosa up in the submucosal plane enables placement of a snare over the entire lesion and deepens the vertical excision plane. It allows sessile, flat or depressed lesions to be removed *en bloc*. Once lifted, the lesion may be snared and excised using cautery. Modern electrocautery units differ in their performance, and endoscopists must be familiar with these devices when treating right- or left-sided lesions. The fluid cushion not only guides the

excision plane but also acts as a thermal cushion, reducing transmural injury. There is no consensus on which fluids to use as a lifting solution. Normal saline is still widely used, but more viscous fluids, such as intravenous colloids, glycerol or hyaluronic acid, are slower to disperse; saline tends to give only a short-lived lift. Dilute epinephrine is often added to aid haemostasis, and dyes such as indigocarmine or methylene blue have been used to show the extent of the cushion, the edge of the lesion and the fibres of muscularis propria beneath. Technical details and refinements can be viewed in Repici *et al.* [70] and Waye *et al.* [71].

The margins of the lesion in circumferential and vertical directions are again critical for adequate potentially curative local treatment. Visual assessment of an excision site immediately after resection requires dye spray or NBI/FICE. Residual neoplasm is resected with mini-snare or is treated with argon plasma coagulation (APC) to control recurrence of neoplasia. If the lesion is incompletely excised on histological grounds further therapy will be necessary. Localization by tattoo (see later) is essential.

Piecemeal endoscopic mucosal resection

Sessile or flat lesions more than 20 mm in diameter with favourable morphological and surface pit patterns can be resected using piecemeal EMR (pEMR). Progressive lifting and snare excision will remove a lesion but yield multiple specimens without orientation and with neoplasia at several cut edges. This violates the principle of *en-bloc* resection but might prove adequate for local control in an unfit person. The histopathology specimens are more difficult to interpret, and prediction of prognosis is harder still. On this basis, when a lesion has any features suspicious for malignancy this should not be the preferred treatment modality. LST-G tumours are suitable for pEMR if benign on close inspection. Some LST-G contain more prominent nodules which can contain malignant change. These nodules should be excised first and sent separately [47].

Once excised, all parts of the polyp will need to be removed using a Roth Net or polyp trap and suction. The piecemeal excision site should be clear of both mucosa and submucosa (i.e. down to the muscularis propria). Any neoplastic remnants will lead to recurrence. To reduce recurrence, APC of the mucosal edge has been used with success [72,73].

A warning has come from Moss *et al.* [64] who found prior use of APC in large EMR to be a risk factor for recurrence and therefore potential spread. However, this may reflect inadequate primary treatment. This would arise where a compromised pEMR is patched up by APC. This Australian series is from a tertiary centre

with a referral practice – reiterating the message that endoscopists need to know their limits and refer on for expert management.

Findings

Piecemeal EMR cannot deliver an en-bloc resection and hampers histopathological assessment of the lesion (Level III).

Recommendation

Piecemeal EMR is not recommended when there is endoscopic suspicion of malignant change in a polyp (Grade C).

Endoscopic submucosal dissection

Endoscopic submucosal dissection (ESD) offers the opportunity of an *en-bloc* resection of a colorectal lesion [74,75]. Even large lesions with potential malignant change can thus be excised endoscopically. After the submucosal lift, mucosal incision is performed followed by submucosal dissection using one of a number of specialized endoscopic knives. Critical to this is to control haemostasis throughout. Addition of a plastic cap to the end of the endoscope allows more stability, precision cutting and provides good orientation of the planes. This facilitates retraction and further dissection. ESD offers *en-bloc* specimen excision and can, in skilled hands, be used to re-excite areas of previous recurrence or through an area of scarring made by previous resection attempts. Japanese experience is extensive: Saito *et al.* [76] presented the results of 1111 colorectal ESDs, including severe dysplasia, superficial invasion and deep submucosal invasion. They had *en-bloc* and curative resection rates of 88% and 89%, respectively. Even in these expert hands, however, the perforation rate was high (4.9%) and bleeding occurred in 1.5% of cases.

European and US experience is accumulating but the technique is demanding and time consuming [77]. Deprez *et al.* [78] reported a consensus statement by European endoscopists, recommending, in particular, the training necessary to gain expertise in this demanding technique. The learning curve is long, but necessary [74,79]. Several endoscopists in the UK currently perform ESD.

Transanal endoscopic microsurgery

Transanal endoscopic microsurgery (TEMS) is the surgical equivalent in the rectum of ESD. It offers the additional opportunity, if required, of full-thickness excision and closure of the rectal defect. This modality is considered further below.

Thus, there are a number of endoscopic techniques for removing a potentially malignant colic polyp. Table 7 summarizes the suggested management of polyps based on their size and Paris/Japan Classification.

Findings

When malignancy is suspected in a polyp the treatment aim must reflect risk of submucosal invasion and estimation of the extent. En-bloc resection must be the aim, achieving proper lateral and vertical clearance. The technique (and endoscopist) should be chosen with this intent. Surgery, including transanal endoscopic microsurgery, must be considered when satisfactory endoscopic clearance fails or is inappropriate. Patient factors and informed choices guide decision-making (Level III).

Recommendation

Patient-centred treatment choices include endoscopic management of potentially malignant polyps when en bloc clearance of predicted malignant polyp is achievable (Grade B).

Table 7 Summary of treatment options based on size and morphology.

Polyp classification	Polyp size (mm)				
	< 5	6–10	11–15	16–20	> 20
0-Ip	SS	SS	SS	SS	SS
0-Is	SS or EMR	EMR	EMR	EMR	pEMR
0-IIa, b 0-IIa+b	EMR	EMR	EMR/ESD	ESD/Surg	Surg
0-IIc	EMR	EMR/ESD	Surg	Surg	Surg
LST-G	–	–	EMR	pEMR/ESD	pEMR/ESD
LST-NG	–	–	EMR/ESD	ESD	ESD/Surg

EMR, endoscopic mucosal resection; ESD, endoscopic submucosal dissection; LST-G; lateral spreading tumour with a granular surface; LST-NG, lateral spreading tumour with a nongranular surface; pEMR, piecemeal EMR; SS, simple snare polypectomy; Surg, surgical resection.

Suggested management policy for polyps based on size and Paris/Japan Classification. Chromoendoscopy for pit pattern and/or narrow band imaging (NBI) assessment will modify the approach, as will polyp location, access and patient factors.

Complications of endoscopic methods

Quoted complications from polypectomy vary widely depending on the patient group and therapy. Overall colonoscopy complications in the recent British Society of Gastroenterology/Association of Coloproctology (BSG/ACP) audit were low: the perforation rate was 0.04% (1 in 2511 procedures); bleeding occurred in 0.26% (1 in 386 procedures) and the unplanned admission or episodes of unplanned care postcolonoscopy was 0.14% (1 in 693)[80]. In the English Bowel Cancer Screening Programme, analysis of the first million people invited reported that 17 192 had colonoscopy as the first investigation after a positive HaemoccultTM (Beckman Coulter (UK) Ltd, High Wycombe, UK) faecal occult blood test. Serious colonoscopy-related complications were rare. Forty-two patients had bleeding – only 12 requiring hospital admission. Seventeen patients had colonic perforations and 14 patients had postprocedural pain [11].

The Munich Polypectomy Study [81] looked prospectively at 4000 polypectomies in a multicentre study. The authors divided complications into major (death, perforation, significant post polypectomy bleeding or recurrent bleeding after treatment) or minor (bleeding manageable during the same endoscopic session). The overall perforation rate was 1.1%, with 45% of these being managed endoscopically. Overall, 9.7% polypectomies lead to complications. Table 8 shows risk by site and size of polyp. Where multiple polyps were resected there was a higher rate of complications overall (13.2%) and of major complications (4.1%).

Findings

Risks of complication following endoscopic therapy are quantifiable and should inform discussions with patients and selection of techniques and endoscopist or surgical resection (Level III).

Table 8 Complication rates according to size of polyp, morphology and site.

Polyp size (cm)	Polyp location and morphology			
	Left colon		Right colon	
	Pedunculated (n = 987)	Sessile (n = 1577)	Pedunculated (n = 118)	Sessile (n = 1294)
< 1 cm	0 (250)	0.4 (950)	1.9 (54)	1.2 (729)
1.0–1.9 cm	0.6 (512)	0.9 (438)	3.9 (51)	3.5 (402)
≥ 2 cm	3.6 (225)	5.3 (189)	0 (13)	11.7 (163)

Values are given as % (n). Major complication rates associated with polyps (not patients) are expressed as percentages, and their relation to polyp size, morphology and location are presented. Complication rates above 3% are given in bold. (Redrawn from Heldwein *et al.*, [81] Munich Polyp Study). The information given shows that even 1 cm sessile right-sided polyps have an appreciable risk of complications. Such information should influence consent and treatment discussions with patients, and be borne in mind when balancing the risk of surgery in an individual.

Recommendations

Risk of complications can be predicted and contribute to treatment decisions (Grade B).

Role of tattooing in endoscopic practice

Tattooing during colonoscopy serves three purposes:

- 1 To allow reliable surveillance of previous endoscopic excision sites.
- 2 Localizing previously seen indeterminate areas of pathology for later re-examination.
- 3 Accurate localization of lesions, possibly or definitely requiring surgical excision.

An indelible mark in the colonic mucosa can be placed by tangential injection of aliquots of either carbon particles (India ink or SpotTM, Diagmed Healthcare Limited, Thirsk, UK) or indocyanine green. The technique currently preferred is to inject into a bleb of submucosally injected saline [82]. Surgery is undertaken with the aim of resecting any potential nodal and mural disease [83]. If a polyp has clearly been located in the caecum then tattooing can sometimes be omitted because right hemicolectomy is likely to be undertaken. However, if the polyp lies anywhere between the caecum and the low rectum, tattooing is usually essential at endoscopy [84] to aid localization at surgery and to ensure resection of the correct segment of colon and/or rectum. In the absence of colonic tattoos, lesions requiring surgery can be missed, especially by laparoscopic colectomy, when they are impalpable or invisible on the serosal surface [85,86]. Each endoscopy unit requires an agreed tattoo policy among all endoscopists and surgeons. For potential surgical excision, three or four quadrant tattoos are sufficient. Usually these are placed on the distal (anal) side of lesions. There is debate on the number, site and technique used. There

needs to be close team-working among endoscopists and surgeons, and unambiguous terminology on endoscopic reports in terms of caudal/anatomically distal/anal canal side tattoo positioning *vs* cranial/proximal/ileocaecal positioning.

Where a polyp-excision site is to be surveyed, a single tattoo at, or adjacent to, the area can be used. The English National Health Service (NHS) Bowel Cancer Screening Service requires a tattoo to be placed to localize any polyp-excision site where the polyp is over 1 cm in diameter. If a polyp unexpectedly is found to be malignant the tattoo will allow accurate localization for surveillance or subsequent surgery, as indicated. When no tattoo has been placed, a very early re-scope and tattooing is indicated. There may only be any indication of the excision site for between 7 and 14 days.

Findings

Tattooing to localize pathology is required for accurate follow up and localization at surgical resection (Level II).

Recommendations

Lesion tattooing following agreed protocol is essential (Grade B).

Follow up

The purpose of endoscopic follow up after treatment of malignant polyps is:

- 1 Detection of recurrence at the treated site.
- 2 Treating metachronous disease.
- 3 Detection and removal of advanced adenomas to minimize interval colorectal cancer and mortality.

The BSG/ACP recommendations, published first in 2002 and revised in 2010, lay out clear guidance on postpolypectomy surveillance for adenomatous polyps [87,88]. The number and size of polyps resected at index colonoscopy determines the surveillance regimen. Individual patient factors influence decision-making. Following surgical resection of malignancy the recommendation is a follow-up colonoscopy 5 years postsurgery, if the perioperative colonoscopy is otherwise clear. After surgery for invasive cancers, there is no evidence that surveillance colonoscopy improves survival, despite treatable polyps and advanced adenomas being found. If these patients have other adenomas, follow up is scheduled by the BSG/ACP adenoma guidelines and this may be more intense: many endoscopists find this a paradox. Patients who have developed a colorectal cancer appear to have a surveillance regimen less intense than do those with benign disease.

For endoscopically removed malignant polyps the BSG/ACP guidelines recommend surveillance of the excision site by re-scope at 3 months. If there is any

doubt about completeness of excision, for example following pEMR, then a further examination 6 months later is recommended. If there is no recurrence then surveillance reverts to the BSG/ACP surveillance guidelines. Less intense regimens were based on findings by Eckhart [8], who showed no difference in metachronous disease between patients followed up after benign polyp excision and those followed up for severely dysplastic or malignant polyps. In the USA, a 3-month postresection follow-up of the site itself, and then follow-up colonoscopy, is recommended at 1, 3 and 5 years postresection [89–91]. The most recent US guidelines, by the US Multi Society Task Force (MSTF) on Colorectal Cancer, specifically exclude follow up of malignant polyps [92]. Repici *et al.* [70] recommend a more intensive follow up after EMR. They state 1- to 3-month follow-up examinations throughout the first 2 years after piecemeal resection of early colorectal cancer. When an *en-bloc* excision of early colorectal cancer has been performed, 3- to 6-monthly follow up for the first 2 years is suggested. This is based on evidence that with larger and more numerous polyps there is a higher rate of metachronous advanced adenomas [93,94].

From Australia, Moss *et al.* [64] published their tertiary-centre experience of follow up of advanced adenoma > 2 cm in diameter, including early colorectal cancers, and recommended intensive initial surveillance over the first year to 14 months, based on a high local recurrence rate (20%) following large piecemeal excisions. Once recurrences were treated, follow up was less intense and local recurrence was much lower.

A large study, pooling eight other studies [94], examined metachronous advanced adenomas (defined as adenoma of 10 mm or greater in diameter, and with at least 25% villous features or having high-grade dysplasia). Their pooled cohort amounted to 9167 patients who had undergone colonoscopy and polypectomy for benign polyps and were followed up over a medium of 48 months. In this medium follow-up period, around 1 in 10 patients developed a metachronous advanced colorectal neoplasm and approximately 1 in 150 developed an invasive colorectal cancer. These risks are related to the number of original adenomas, their size, location (right-sided lesions being more predictive of recurrence or further polyps than left-sided lesions) and histological features such as villous elements, increasing patient age and male sex. The paper mostly provides reassurance that risk stratification by both BSG/ACP guidelines or by the US MSTF on Colorectal Cancer are indeed appropriate. It did not specifically address the issue of malignant polyp follow up but argued for surveillance of larger multiple polyps with higher risk for metachronous,

advanced neoplasia formation, and suggested further factors to be considered, specifically polyps in older patients, more proximal lesions in men and those polyps with high-grade dysplasia.

Findings

Follow up is required after either endoscopic or surgical excision of colorectal neoplasia to detect early recurrence, treat recurrence and minimize the risk of metachronous disease. The timing of such follow up is subject to debate. When endoscopic resection of a malignant polyp has occurred, local luminal recurrence can be monitored by repeat endoscopy, initially early, with the intensity of follow up guided by risk and findings (Level III).

Recommendations

Colonoscopic follow up after malignant polyp excision or resection should be performed according to current guidelines (Grade C).

B: Pathology of malignant colorectal polyps

Introduction

Adenomatous polyps are epithelial neoplasms graded histologically by the degree of dysplasia (Vienna Classification; low or high grade with an additional category of invasive carcinoma)[95]. The NHS Bowel Cancer Screening Programme (BCSP) reporting guidelines recommend using two categories – low-grade dysplasia and high-grade dysplasia – in which high-grade dysplasia includes the now abandoned categories of carcinoma *in-situ* and intramucosal carcinoma [96].

Pathology of colonic polyps and malignant change

Adenomatous polyps

It is well recognized that more than 95% of colorectal cancers arise from adenomatous polyps [97,98]. The so-called ‘classical’ adenomas are benign neoplasms composed of dysplastic glandular epithelium and represent up to three quarters of screen-detected colorectal neoplasms in reported series [99,100]. By definition, all adenomas show dysplasia, divided into low or high grade [101] and architecturally into tubular, tubulovillous or villous types, according to the World Health Organization (WHO) Classification [102].

In screening programmes such as the BCSP, the majority of polyps are tubular adenomas (48–55%), with lower reported frequencies of tubulovillous (15–24%) and purely villous (1–6%) subtypes [103]. The reported prevalence of high-grade dysplasia varies between 5% and 14% [103].

There is a higher overall prevalence of polyps in screening populations, and screen-detected lesions appear more likely to be adenomatous compared with those in symptomatic patients (72–79% *vs* 47–62%, respectively)[104]. Lower proportions of purely villous and high-grade lesions have been identified in symptomatic cases [105,106], while screen-detected lesions show higher rates of large (> 10 mm) or multiple polyps and adenocarcinomas.

High-grade dysplasia shows complex glandular crowding and irregularity, prominent budding, cribriform architecture with ‘back-to-back’ glands and prominent cellular atypia [96,107]. The latter includes loss of cell polarity or nuclear stratification, markedly enlarged nuclei with a dispersed chromatin pattern and a prominent nucleolus, abundant mitotic figures with atypical mitoses and prominent apoptosis. The revised ‘high-grade’ category includes focal infiltration of carcinoma cells into the lamina propria and so includes lesions previously described as carcinoma *in-situ* or intramucosal carcinoma. Use of the latter terms is now discouraged to reduce the risk of overtreatment in noninvasive lesions [108].

‘Malignant’ polyps

A malignant colorectal polyp is a lesion in which neoplastic cells have invaded through the muscularis mucosae into the submucosa [13,69,109,110]. A pT1 adenocarcinoma is defined as invasion into the submucosa but not into the muscularis propria [111]. Higher rates of malignancy have been described in purely villous adenomas (10–18%) compared with tubulovillous (6–8%) and tubular (2–3%) types [108].

Malignant potential in a polyp correlates with increasing size and patient age [106,112]. Size is one of the most important risk factors for malignant transformation. In one series, of 5137 adenomas of diameter of < 5 mm, none demonstrated malignant transformation [41]. There is substantial evidence that large polyp size correlates with villous morphology and high-grade dysplasia. In a recent study of 13 992 asymptomatic patients undergoing screening colonoscopy, the proportion of adenomas with high-risk features (villous or serrated architecture, or high-grade dysplasia) was 1.7% in lesions measuring 1–6 mm, 6.6% in lesions measuring 6–9 mm and 30.6% in those larger than 10 mm [113,114]. Larger polyps are associated with a greater risk of malignancy (up to 80% of adenomas exceeding 42 mm)[40,115]. In one study it has been estimated that the risk of carcinoma in an adenoma of up to 1 cm is < 1%, rising to 10% in adenomas measuring 1–2 cm and to 20–50% in adenomas larger than 2 cm [116]. It seems that the use of the pathologist’s microscopic

measurement is currently the most accurate method of assessing size.

Findings

Pathology measurements are auditable, accurate, simple to perform and able to assess the size of the adenomatous component of mixed lesions (Level IIa).

Recommendations

Measurement of these parameters should be performed to the nearest millimetre [116] on all colonic polyps (Grade B).

Serrated lesions

Serrated lesions [117–120] have only recently been highlighted as having distinct genetic features and a different architecture compared with classical adenomas. The family of serrated polyps comprises sessile serrated adenomas, also called sessile serrated polyps (SSA/Ps), traditional serrated adenomas, hyperplastic polyps, and mixed hyperplastic/adenomatous polyps or admixed polyps [121]. Serrated polyp is a term coined initially by Longacre and Fenoglio-Preiser in their classic paper in 1990 [120]. These polyps form an important part of the newly recognized range of lesions that share some architectural features of serration (festooning) and develop, via different genetic mechanisms, (methylation) to adenomas. Previously these serrated lesions were diagnosed as hyperplastic or metaplastic polyps and were considered innocuous. The late Jeremy Jass was the first to provide evidence for their malignant potential [117]. The new classification proposed by Snover *et al.* [122], on behalf of the WHO, caters for all these subsets (Table 9). In serrated polyps, the adenoma–carcinoma sequence is accelerated and runs faster than the APC mutation counterpart in adenomatous polyps [122]. There is also a relationship between size and risk of malignancy [123].

Resection technique

The technique of resection is important as it determines whether the resected polyp can be assessed fully by the pathologist, allowing an accurate prediction of the risk of lymphovascular dissemination and recurrence. This is seldom a problem with pedunculated polyps as the presence of a stalk allows reliable assessment of depth of invasion, but sessile polyps are frequently excised in a

piecemeal manner, thus making assessment of adequacy of resection more difficult. Dell’Abate *et al.* [124] reported that polypectomy of giant polyps (defined as > 3 cm) was safe and effective, but 38% of these resected polyps showed invasive carcinoma. Of these, 67% were judged to be completely excised and if the polyps did not exhibit lymphovascular invasion or poor differentiation, the patients remained well during the median follow up of just under 3 years. Patients with incomplete excision were treated in a variety of ways, with the resulting difficulty in interpreting the various outcomes. *En-bloc* EMR is particularly useful for sessile polyps > 2 cm in diameter, traditionally the most difficult group to resect and often requiring piecemeal resection.

For rectal polyps, the method of resection (endoscopic *vs* transanal; full-thickness excision *vs* mucosectomy or partial-thickness excision) is at least partly determined by a requirement to provide the best possible specimen for histological analysis. The proponents of EMR believe that polyps of almost any size can be removed using this technique, but the larger the lesion the more likely the excision specimen is to be disrupted and fragmented and hence more difficult to assess histologically. If the upper part of the lesion can be palpated digitally, it may be suitable for standard transanal excision. TEMS is a technique for local excision of rectal tumours. This method greatly improves accessibility, visualization and precision of resection of early rectal tumours compared with the standard transanal method. Using a 40-mm proctoscope with magnified binocular vision, the rectum is insufflated with carbon dioxide and laparoscopic-style instruments are introduced through airtight ports. The rectal tumour is removed by sharp dissection under direct vision with a 1 cm margin of normal tissue. For malignant lesions, the muscular wall of the rectum is removed with the specimen. TEMS is able to reach lesions at any height and position in the rectum and there is some reasonably good evidence that it produces a better resection specimen than do standard transanal techniques [125,126]. There are proponents of full-thickness excision as the standard treatment for sessile rectal polyps, even if the lesion is in the intraperitoneal part of the rectum. Other surgeons will tailor the treatment to their preoperative assessment: mucosectomy for those lesions expected to be benign; and full-thickness excision with a 1-cm margin for clinically or histologically proven malignant lesions that appear to meet the criteria for curative local excision. Decisions about further management are then made following histopathological analysis of the specimen. Data from the UK TEMS Cancer Database have demonstrated that when patients with unfavourable histology following TEMS excision proceed directly to

Table 9 Classification of serrated lesions.

1	Hyperplastic (metaplastic) polyp
2	Sessile serrated adenoma/polyps without dysplasia
3	Sessile serrated adenoma/polyp with dysplasia (previously called mixed polyps)
4	Serrated traditional adenoma

rectal excision, there are no adverse oncological consequences [127]. Thus, TEMS for rectal polyps can be considered to be a 'big biopsy' that provides further histological information used to inform decisions about further treatment. As for early colon cancer, the pathological assessment is used to predict the risk of incomplete resection and nodal metastases.

Pathological prognostic factors

Many factors have been associated with a higher probability of residual disease or recurrent carcinoma and as such should be assessed by the pathologist examining an excised colorectal polyp.

Level of invasion into the polyp

Haggitt levels

Haggitt [128] level of invasion in a pedunculated polyp is an important prognostic factor and is defined as follows (Figs. 3):

- Level 1. Carcinoma invading into the submucosa, but limited to the head of the polyp.
- Level 2. Carcinoma invading to the level of the neck (the junction of the head and stalk) of the adenoma.
- Level 3. Carcinoma invading any part of the stalk.
- Level 4. Carcinoma invading into the submucosa of the bowel wall below the level of the stalk.

Level 4. Carcinoma invading into the submucosa of the bowel wall below the level of the stalk but above the muscularis propria.

Invasive cancer arising in a sessile adenoma is, by definition, a Level 4 lesion.

Kikuchi levels

Kudo [44] looked at endoscopic submucosal resection of sessile and depressed early colorectal carcinomas. This group were the first to divide submucosal invasion into sections classified as sm1, sm2 or sm3, based on the depth of submucosal penetration. Kikuchi and colleagues [129] modified the classification of sessile lesions (pT1 cancers, not invading the muscularis propria) and divided the submucosa into thirds. Tumours involving only the uppermost third are further subdivided based on the extent of horizontal spread of tumour. The Kikuchi Classification is defined as follows (Figs. 4):

- sm1. Tumour invasion of the upper third of the submucosa.
- SM1a: less than a quarter of the width of the tumour invading the submucosa.
- SM1b: between a quarter and a half of the width of the tumour invading the submucosa.

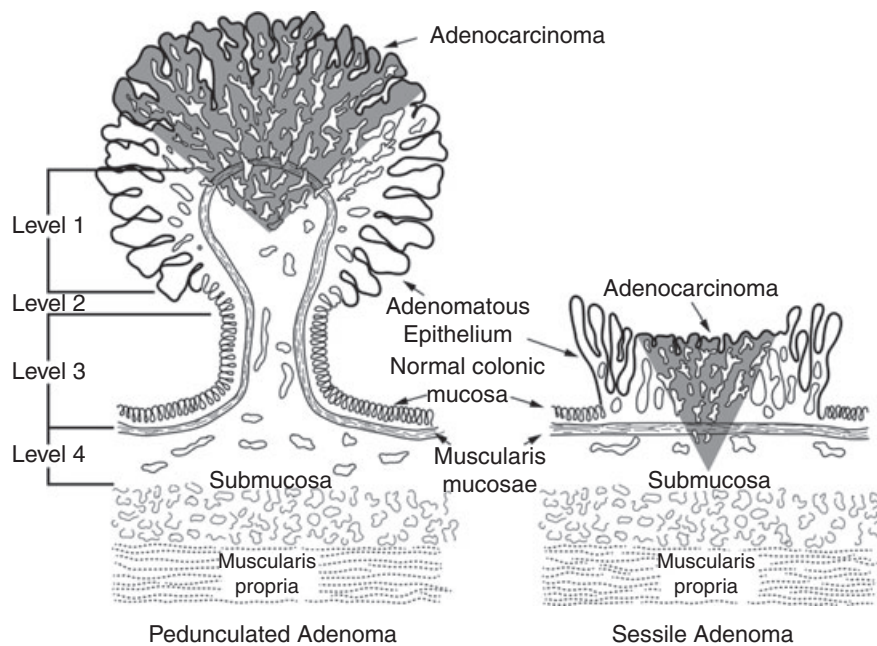


Figure 3 Haggitt classification of depth of invasion of pedunculated and sessile malignant polyps. The focus of invasive cancer is represented by dark shading as having penetrated through the muscularis mucosae to Level 1 (carcinoma limited to the head of the polyp). Level 2 is where carcinoma invades to the level of the neck (the junction of the head and stalk) of the adenoma; Level 3 is where carcinoma invades any part of the stalk; and Level 4 is where carcinoma invades into the submucosa of the bowel wall below the level of the stalk. In the sessile adenoma a stalk is absent and so, by definition, the lesion is defined as being Level 4.

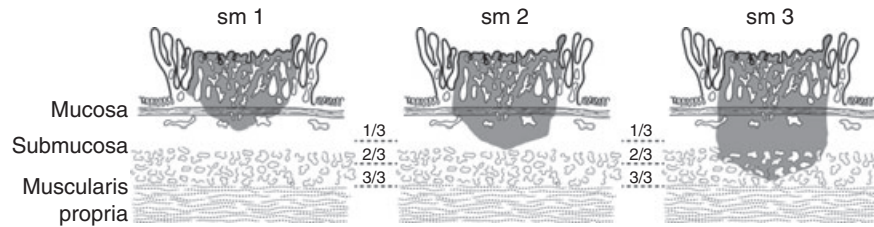


Figure 4 Kikuchi Classification of the depth of invasion into submucosa of a sessile malignant polyp. The focus of invasive cancer is represented by dark shading as having penetrated through the muscularis mucosae. An sm1 tumour invades into the upper third of the submucosa, an sm2 tumour invades into the middle third and an sm3 tumour invades into the lower third of the submucosa.

SM1c: more than a half of the width of the tumour invading the submucosa.

sm2. Tumour invasion of the middle third of the submucosa.

sm3. Tumour invasion of the lower third of the submucosa.

It is important to emphasize that the Kikuchi system is more difficult to use if there is no muscularis propria in the biopsy, and the Haggitt system is of no value in sessile lesions as measurement depends on a recognizable submucosa and good orientation of the polyp [96,101]. An alternative system, based on measurement of the depth of invasion beyond the muscularis mucosae, was developed by Kitajima *et al.* [130], who correlated the depth of invasion with risk of lymph node metastasis in a pooled series of 864 patients who had undergone surgical rather than endoscopic resection for submucosal invasive colorectal cancer. This system has been adopted in Japan and, more recently, Ueno *et al.* [131] adopted this system of measurement to endoscopically excised malignant polyps. However, again, this system can be difficult to use in routine practice and its use is not widespread in the UK.

Findings

Depth of invasion can be assessed on the basis of validated descriptive systems or by direct measurement of invasion below the muscularis mucosae, which will yield important prognostic information, provided that the polyp has been removed intact and processed correctly (Level IIa).

Recommendation

The pathologist must endeavour to make an accurate assessment of the depth of invasion of the cancerous cells into the submucosa (Grade A).

Pseudoinvasion/epithelial misplacement

Pseudoinvasion is the presence of benign mucosal glandular epithelium beneath the muscularis mucosa in colonic polyps; there is no malignant potential and the

lesions should be treated in a similar way to adenomas [96]. Pseudoinvasion is rare, but when present usually occurs in large polyps (> 1 cm), especially those with long stalks, and is most commonly found in the sigmoid colon. The displaced glandular tissue, which can be mistaken for cancer, usually has rounded contours and is surrounded by lamina propria, and is cytologically identical to the overlying adenomatous component. Haemorrhage and haemosiderin deposition are commonly seen and are a clue to diagnosis. In addition, inflammation and granulation tissue can be found [132]. Occasionally, rupture of dilated glands occurs with acellular mucin extravasation and there is a subsequent inflammatory response. Distinction from mucinous (colloid) carcinoma is important and can be difficult. Specifically, in mucinous carcinoma, the mucin pools contain malignant cells, a feature lacking in pseudoinvasion. For these reasons it is highly recommended that multilevel sections and second opinions are obtained in these cases [133]. Particular care should be exercised when interpreting the histology of a lesion that has already undergone some form of partial resection (for example a TEMS specimen following previous partial polypectomy). In this situation there is often glandular displacement into the submucosa which could be interpreted as invasive cancer. For this reason, it is important that the histology request form includes all details of the management of the lesion before resection.

Polypectomy resection margins

The importance of ensuring a histologically assessed resection margin free of cancer is universally agreed, but there is no universal agreement about the minimum safe margin of clearance. It is well known that diathermy artefact at the margins of the resected specimen can make it difficult for the pathologist to provide an accurate definition of the presence or absence of invasive cancer cells at the resection margin. This is less of a problem for pedunculated polyps, where a resection margin is typically some distance from the invasive component of the polyp. It is especially difficult for the pathologist to

determine local clearance when sessile polyps have been excised in a piecemeal manner. Completeness of excision of the deep and lateral mucosal margins is important as surgery could be indicated when the former is involved; further local excision may be attempted if the lateral mucosal margin is believed to be involved, particularly if the lateral margin is involved with a benign component of the malignant polyp [101].

An involved margin has different definitions in the literature. There is no consensus about what represents a 'negative margin', which has been defined variously as: one in which cancer is not within the actual diathermy edge [110]; more than one high-power field from the diathermy edge; > 1 mm from the margin [69]; and more than 2 mm from the margin [134,135]. Current European guidelines recommend that clearance of ≤ 1 mm of malignant cells is regarded as indicative of margin involvement [116].

Findings

Polypectomy resection margin is an important prognostic factor, although this can be difficult to assess where a polyp has been excised piecemeal. There is no uniform definition of an involved margin (Level IIa).

Recommendation

The pathologist must endeavour to assess whether the invasive element of a polyp has been completely excised and by how great a margin (Grade GP).

Histological grade

Well-differentiated carcinomas have well-formed glands with > 95% glandular differentiation. Poorly differentiated adenocarcinomas demonstrate only focal glands with 50–95% glandular differentiation. The majority of carcinomas, however, are generally classified as moderately differentiated and fall between the two in appearance. Poorly differentiated cancers comprise 5–10% of cases and are associated with a significantly greater incidence of metastatic disease than are better differentiated tumours [136,137] (see the section on Cancer differentiation).

Tumour budding

Tumour budding is defined as isolated single cancer cells or small clusters (fewer than five cells) of cancer cells at the advancing edge of the tumour. Several studies have defined a tumour as positive for budding when there are five or more buds per 20 power fields [131,138]. Studies of pT1 cancers have shown that the presence of tumour budding is significantly associated with lymph node metastasis and other adverse outcomes [130,131,138,139].

Cribriform histology

Cribriform histological pattern is defined as gland within gland and/or back-to-back arrangement without stroma in between. pT1 cancers with a cribriform histology were associated with a significantly increased risk of lymph node metastasis on multivariate analysis, although this was not as great as for lymphatic channel involvement [140].

Lymphovascular invasion

Lymphatic invasion by a cancer is defined as tumour cells visible within a true endothelial channel in the absence of erythrocytes [141]. Whilst this simple definition seems clear-cut, there are difficulties in assessing lymphatic invasion in a malignant polyp. First, it may be difficult to differentiate true lymphatic invasion from fixation artefacts in paraffin sections. Second, there is no agreed protocol for assessing lymphatic invasion, such as the number of sections to be reviewed or the use of specific immunocytochemical stains. For these reasons, interobserver variation in the assessment of lymphatic invasion is high (see the section on Interobserver variation). Vascular markers, such as CD31 or CD34, may help in assessing vascular invasion. These markers stain blood-vessel endothelium strongly but stain lymphatic endothelium less strongly [133]. Their routine use has not been recommended. The prevalence of venous invasion in malignant polyps varies greatly from one study to another, ranging from 3.5% to 39% [142]. The presence of lymphovascular invasion increases the risks of regional lymph node involvement (see the section on Lymphovascular invasion, p. 22).

Interobserver variation

Interobserver variability amongst pathologists in the classification of histological grade and level of invasion tends to be high. Komuta *et al.* [143] showed that agreement amongst experienced gastrointestinal pathologists who reviewed the slides of 88 malignant polyps was high for T-stage ($k = 0.725$) and depth of invasion ($k = 0.682$), as well as resection margin status and Haggitt level. Agreement between experienced pathologists was poor with regard to histological grade of differentiation and in the assessment of lymphovascular invasion ($k = 0.017$). For adenomatous polyps, van Putten *et al.* [144] showed, in a study of 444 polyps, that moderate agreement was found between general and expert pathologists, and between expert pathologists for categorization of adenomas as nonadvanced or advanced (adenomas of at least 10 mm, having villous

histology or with high-grade dysplasia). Consultation between pathologists within the multidisciplinary team is mandatory, should substaging and evaluation of high-risk features for residual disease indicate the need for surgical resection [131,145].

Findings

Histological assessment of malignant polyps is open to considerable interobserver variation, particularly with regard to the important risk factors of degree of differentiation of the malignant component and the presence or absence of lymphatic invasion (Level IIa).

Recommendations

Pathologists should be prepared to seek a second opinion from another colleague where there is any doubt about histological findings, especially where surgery may be contemplated (Grade C).

Polyp preparation

To have the maximum prognostic/histological information from a polyp it does need to be processed optimally and examined in full [146,147]. This is the dual responsibility of the Endoscopist and the Pathologist. The Endoscopist should provide the following information:

- 1 Size of the polyp.
- 2 Site of the polyp.
- 3 Pedunculated or sessile.
- 4 Was the polyp removed in one piece or piecemeal?
- 5 Assessment of completeness of excision.
- 6 Endoscopic impression of whether benign or malignant (see the section on Prediction of histological features of polyps from endoscopic appearance)

Once the polyp is removed – and to achieve the best preparation the polyp benefits from being received fresh – it is examined immediately by the pathologist or laboratory practitioner, pinned onto a cork board with a stretched stalk (in the case of a pedunculated polyp) and should be left to fix for at least 24 h (even 48 h for larger polyps). After fixation, serial sectioning along the stalk in the case of a pedunculated polyp, and serial sections through the entire sessile polyp, will ensure satisfactory assessment of Haggitt's levels and Kikuchi staging in cases of malignancy. Failure to have good fixation may lead to 'gaps' within the sections as the degree of penetration of the fixative material varies within the same specimen. A long time period of fixation should minimize this variable and ensure uniform representation of the various components of the polyp in one or more section. Morson *et al.* [147] suggested that whenever possible, the entire polyp should be embedded to one side and cut all the way through the stalk to show the entire microanatomy in one section.

They also suggested that side trimming should be minimized or avoided completely. This, however, is not always possible unless large sections, cut with a large microtome, are obtained. This technique is not available in many pathology departments. If there is imperfect retrieval, processing or sectioning, the polyp microanatomy cannot be well represented, potentially leading to inadequate assessment of pathological features.

Histopathologists can easily distinguish neoplastic polyps (adenoma and carcinoma) from non-neoplastic polyps, such as inflammatory, hamartomatous or hyperplastic polyps, in biopsy tissue. It is more difficult to differentiate benign from malignant neoplastic lesions as the biopsies may not show invasion into the submucosa. One study addressing this issue found an 18.5% false-negative rate when comparing the biopsies with the whole specimen [148]. For this reason, histopathology reports should include the caveat that there 'is no evidence of malignant transformation in the tissue examined; however, if this is part of a larger lesion, then a more sinister pathology cannot be excluded'.

C: Assessing the risk of residual disease postpolypectomy

For the purposes of this statement, malignant polyps of the colon and rectum have been considered together as they both arise from large-bowel mucosa, through the same pathways. Whilst this is convenient, there are differences in the two sites that are reflected in the different techniques used for excision of a polyp from the colon and from the rectum. Full-thickness excision is easier to perform in the rectum, using either a traditional transanal procedure or TEMS. Thus, resection of 'early' rectal tumours may include T2 and even T3 tumours, as well as T1 lesions. Furthermore, the treatment algorithms for rectal cancer have become more complex with the growing trend to use adjuvant radiotherapy either preresection or postresection where histology is less favourable.

The traditional treatment of a carcinoma of the colon or rectum is radical resection of the segment of bowel containing the tumour, together with the regional lymphatics; a process associated with significant morbidity and mortality. Up to the late 1980s, many units had a policy of recommending segmental resection following endoscopic removal of a polyp containing a focus of invasive cancer because of the potential for residual mural or lymphatic disease and the resulting risk of haematogenous spread of the disease [109]. In these cases, polypectomy alone was deemed inadequate treatment. Assessing the risk of residual disease following polypectomy is based

on parameters that predict the risk of locoregional recurrence. These include the size and morphology of the tumour, the technique of resection, the resection margin, the degree of differentiation, the depth of invasion and lymphovascular invasion [132]. Adverse outcome in a malignant colorectal polyp is defined as residual cancer in a resection specimen and local or metastatic recurrence in the follow-up period [134].

Polyp morphology

It is now well established that the risk of lymphovascular metastases is higher with sessile polyps than with pedunculated polyps, and consequently the prognosis with the former is poorer [149]. Cooper *et al.* [17] reported a population-based analysis of colonoscopic polypectomy compared with surgery in 2077 patients treated between 2002 and 2005. They reported that more than one-third of patients with malignant polyps were treated with colonoscopic polypectomy. However, they suggested that polyps which were sessile, as opposed to pedunculated, were less amenable to colonoscopic management and may have been subjected to surgical resection as a first choice. The outcomes were similar in both groups. It should be remembered that the study was observational and there was significant scope for selection bias in the allocation of treatment. Furthermore, little data were included on recognized prognostic indicators other than the degree of differentiation of the cancer.

Margin of resection

Cancer at or near the resection margin on histological examination increases the risk for an adverse outcome [14,131,150]. Boenicke *et al.* [151] reported that the concurrence of histologically positive resection margins and sessile morphology was an important risk factor for lymph node metastases after complete endoscopic removal of malignant colorectal polyps. They observed 105 patients with malignant polyps who underwent polypectomy, just over half of which were in the colon. Only 39 patients had histologically demonstrated tumour-free resection margins. Subsequent surgery was performed or follow-up examinations completed on these patients. Local recurrence or residual carcinoma was noted at the original site of the malignant polyp in three patients and metastases to the local lymph nodes were found in eight (7.6%). They concluded that histologically incomplete removal and lymphatic infiltration showed a significant correlation with the presence of lymph node metastases but not with remnant tumour.

It is generally accepted that the risk of lymph node metastases, residual tumour or recurrence is < 2% in resected malignant polyps where the margin of resection is > 1 mm and there are no other adverse histological features [130,135,152]. Cooper *et al.* [69] reported that when a pathologist detects invasive elements at a resection margin, or when the clearance to the margin is < 1 mm, the rate of recurrence increases to up to 33%. It is widely considered that a negative resection margin of ≥ 2 mm for invasive cancer cells results in a very low probability of residual cancer [69,153–156]. Masaki *et al.* [157] concentrated on the appearance of tumour at the invasive margin. The presence of small nests of tumour cells with poor differentiation or a mucinous appearance at the invasive margin of the tumour (not the resection margin) was associated with an adverse outcome (either lymph node involvement or residual tumour in the wall) in five of 24 (21%) malignant polyps with an unfavourable margin compared with one out of 41 (2.5%) malignant polyps without these unfavourable histological features at the invasive margin.

Most studies have shown that a clearance of < 1 mm has the same clinical significance as cancer at the actual margin [69,134,150] and should be regarded as an indication for further therapy. When the resection margin is involved, or is < 1 mm, the percentage of relapse ranges from 21% to 33% [69]. Further endoscopic options are limited for malignant polyps of the colon that have an involved resection margin. However, for rectal polyps with an involved or uncertain resection margin following standard polypectomy or EMR, further local excision (by way of full-thickness excision) is a reasonable treatment option if there are no other adverse histological features present.

If the deep margin is clear, but the lateral margin shows residual adenoma, further local excision is reasonable (if there are no other adverse histological risk factors). If further local excision is not possible, the patient should, if they are fit enough, be considered for standard surgical resection. This should be performed immediately rather than waiting for detection of recurrent disease as delayed surgery is associated with worse oncological outcomes [127,153,155].

Findings

The presence of cancer at or close to (< 1 mm) the deep resection margin of a resected malignant polyp is associated with a significant risk of residual tumour within the draining lymph nodes or bowel wall (Level IIb).

Recommendations

Where the resection margin is deemed to be involved (< 1 mm) surgical resection of the affected segment of

bowel should be considered, provided that the patient is fit enough to undergo such surgery (Grade B).

Depth of invasion

Haggitt and colleagues concluded that all pedunculated polyps where depth of invasion was less than Haggitt Level 4 (invasion of malignant cells into the submucosa below the base of the stalk) represented a group with a very low risk of local recurrence or locoregional metastases [128,158]. It has been established practice on this basis that such pedunculated lesions are appropriate for endoscopic excision alone in the absence of other negative prognostic factors. Navatvongs [159] reviewed a number of studies showing that the incidence of node involvement in malignant pedunculated polyps, endoscopically resected, with Haggitt levels of invasion 1, 2 or 3, was < 1%. Matsuda *et al.* [160] noted that no large-scale reports existed examining the potential for lymph node metastases in pedunculated malignant polyps according to depth of cancer invasion. They obtained data from seven hospitals in Japan and recruited 384 early invasive colorectal cancers of pedunculated type that had been treated by a variety of means, including endoscopic resection, endoscopy followed by surgical resection and surgical resection alone. They reported an incidence of lymph node metastases of 0% in patients with head invasion only (i.e. Haggitt Levels 1 and 2). They reported an incidence of lymph node metastases of 6.2% in patients for whom stalk invasion was demonstrated. They concluded that pedunculated early polyp colorectal cancers confined to the polyp head could be managed by endoscopic resection alone with a minimal risk of locoregional recurrence.

Kikuchi *et al.* [129] refined this classification of malignant sessile polyps and reported risks of lymph node metastases ranging from 0% in SM1 carcinomas to 14.4% in SM3 lesions. The vast majority of sessile polyps are now graded using the Kikuchi Classification, which refines the group of sessile polyps that are graded as Level 4 in the Haggitt Classification. Park *et al.* [161] studied 54 patients who underwent colectomy for early colon cancer (T1 tumours). Depth of invasion into the submucosa was assessed by the Kikuchi classification. None of 10 sm1 tumours had involved lymph nodes compared with two of nine sm2 tumours and three of 11 sm3 tumours. However, other variables, especially lymphovascular invasion, also played a part in the more advanced lesions. In 46 patients, lymphovascular invasion was not present and only two (4.3%) of these cancers had lymph node involvement compared with three of eight (38%) tumours where there was lymphovascular

invasion. However, Kim *et al.* [162] emphasized that accurate classification of submucosal invasion is complicated in endoscopic mucosal resection specimens where the muscularis is not included in the specimen. In 2002, Nascimbeni and colleagues [159] confirmed that invasion of the lower third of the submucosa represented a significantly higher risk of the development of lymph node metastases compared with earlier disease. The rate of lymph node metastases with sm3 level invasion was 23% in that study. Therefore, lesions that extend to the sm1 or sm2 level, and which do not show unfavourable histological criteria, such as poor differentiation, lymphovascular invasion or resection margins of < 2 mm, may be treated by local excision alone [159]. Pedunculated colonic cancerous polyps classified as Haggitt Level 4, sessile polyps classified as sm1 or sm2 with otherwise unfavourable histology and all sm3 sessile polyps should be considered for surgical resection [159].

Kitajima *et al.* [130] assessed the extent of invasion below the muscularis mucosae by direct measurement using an optical micrometer. For pedunculated malignant polyps, where invasion was confined to the head (0 μ m depth of invasion), there was no risk of lymph node metastasis. Similarly, where there was stalk invasion of up to 3000 μ m there was no lymph node metastasis, provided that there was no evidence of lymphatic invasion. For sessile malignant polyps, the risk of lymph node metastasis was zero if the depth of invasion below the muscularis mucosae was < 1000 μ m.

For rectal malignant polyps the situation is more complex as most will be sessile lesions (pedunculated lesions are unusual in the rectum) and full-thickness excision is often performed. Series of patients in whom TEMS was performed for resection of pT1 cancers demonstrated very variable local recurrence rates, of 2–24% [127,163–165]. Some case series have not used histological selection criteria to guide resectional surgery. T1 and T2 cancers with adverse histological features will have high locoregional failure rates. When total mesorectal excision (TME) is performed for pT1 cancers, nodal tumour deposits are found in 2–23% of cases [159,166,167]. Therefore, histological criteria must be used to determine appropriate management. Radical resection of a pT1 tumour does not guarantee cure as 1.7–6.0% of patients still develop local recurrence and 3% manifest systemic recurrence within 5 years [166–168]. Bach *et al.* [127] used clinical, pathological and follow-up data to construct a predictive model of local recurrence after TEMS using semiparametric survival analyses. This model used tumour size, pT stage, depth of invasion (Kikuchi) and intramural lymphovascular invasion (see Table 10). Local recurrence rates of 3–5% were observed following resection of pT1, sm1

Table 10 Outcome after transanal endoscopic microsurgery (TEMs) resection of rectal cancer.

pT Stage	Kikuchi stage	LyV	Maximum tumour diameter (cm)					
			≤ 1	1.1–2	2.1–3	3.1–4	4.1–5	5.1+
pT1	Overall	–	6.3	7.9	9.8	12.2	15.1	18.6
		+	12.0	14.8	18.3	22.4	27.3	33.1
	sm1	–	3.0	3.6	4.4	5.4	6.6	8.1
		+	5.2	6.4	7.7	9.4	11.4	13.7
	sm2/3	–	10.5	12.7	15.3	18.5	22.1	26.4
		+	17.8	21.4	25.5	30.3	35.7	41.8
pT2		–	9.8	11.9	14.3	17.3	20.7	24.7
		+	16.7	20.0	23.9	28.5	33.7	39.5
pT3		–	19.7	23.6	28.0	33.2	39.0	45.4
		+	32.2	37.9	44.1	51.0	58.3	65.7

Local recurrence rates (%) at 36 months were predicted using the Cox regression model for well or moderately differentiated tumours locally excised using TEMs in patients under 80 years of age. Data were derived from Bach *et al.* [127], according to pT stage, Kikuchi (sm) stage, the presence or absence of lymphovascular invasion (LyV) and maximum tumour diameter.

and well/moderately well-differentiated tumours of < 3 cm in diameter and without lymphovascular invasion. For pT1 sm2/3 or pT2 well/moderately well-differentiated tumours of < 3 cm diameter without lymphovascular invasion, the local recurrence rates were 10–15%. Other factors are likely to influence the risk of nodal disease. Ueno *et al.* [131] proposed that the absolute thickness of the invasive tumour (beyond the muscularis mucosae) provides a further objective measure of the risk of adverse oncological outcomes. In their series, depth of invasion of < 2000 µm into the submucosa was associated with nodal involvement in 5.6% of cases, compared with nodal involvement of 17.7% where submucosal invasion was > 2000 µm. Although this system of assessing invasion by measurement appears simple, most series rely on Kikuchi Staging.

Selective postoperative radiotherapy for those local excision specimens with high-risk histological criteria has failed to deliver satisfactory improvements in disease control [127]. There is currently very little evidence to guide the use of down-staging preoperative chemoradiotherapy and local excision as curative treatment for early rectal tumours. One randomized trial compared the oncological results for T2N0 (Grade 1–2) rectal cancer following laparoscopic total mesorectal excision with local excision following down-staging chemoradiotherapy of 5040 cGy over 5 weeks with continuous infusion of 5-fluorouracil [169]. Seventy patients were randomized equally between the two groups; the median follow up was 84 months. The trial showed similar results between the two groups, with a probability of survival following rectal cancer of 94%. A review of published case series of neoadjuvant chemoradiation and local excision for T2–3 rectal cancer suggested that

those patients with a response to neoadjuvant treatment had low local recurrence rates [170]. There are currently insufficient data to make any meaningful recommendations on preoperative chemotherapy or radiotherapy. Prospective randomized trials are needed. The TEM and Radiotherapy in Early Rectal Cancer (TREC) trial aims to randomize patients between local excision and radiotherapy and standard resection for rectal cancer. It will compare data on morbidity, bowel function and quality of life to test and to determine how patients make clinical decisions in this situation.

A recent systematic review by Smith *et al.* [171], examining the role of rectum-conserving surgery in the era of chemoradiotherapy, reports that the data support transanal excision of rectal tumours showing a good response to chemoradiotherapy. A complete response in the T stage (ypT0) indicates a risk of < 5% of nodal metastases. This approach may result in outcomes equivalent to those following radical surgery and should be tested in prospective trials in specialist centres.

Findings

Depth of invasion measured by Haggitt or Kikuchi systems, or by measuring depth of invasion into the submucosa, is highly predictive of the presence of lymphatic metastasis. The risk of lymphatic metastases is low for pedunculated polyps where the focus of cancer is confined to the head and upper stalk and for sessile lesions with invasion of the superficial part of the submucosa, where there are no other adverse features (Level IIa).

Recommendations

Where invasive cancer reaches the base of a pedunculated polyp (Haggitt Level 4) or the deeper layer of the submucosa of a sessile polyp (Kikuchi Level 3), surgical resection

of the affected segment of bowel should be considered, provided that the patient is fit enough to undergo such surgery (Grade B).

Lymphovascular invasion

Kitajima *et al.* [130] showed that lymphatic invasion was an independent risk factor for lymph node involvement in multivariate analysis of the outcome of patients in a large Japanese series, all of whom underwent surgical resection. Hassan *et al.* [14] performed a pooled-data analysis on 31 studies of malignant polyps which included 1900 patients. The pooled data were from retrospective studies, which limits the data quality, but as there are no large prospective studies this represents the best data available. Hassan's study looked at three histological risk factors (the positivity of the resection margin, poor differentiation and lymphovascular invasion) and five clinical outcomes, namely residual disease, recurrent disease, lymph node metastasis (in patients who had a resection), distant metastasis and mortality. Lymphovascular invasion was present in 18% of polyps. Lymph node metastasis occurred with 35% of polyps when lymphovascular invasion was present and with 7% when it was absent. Eighty-three of the 268 polyps had lymphovascular invasion as the only adverse risk factor. In the group who had lymphovascular invasion as the only potential adverse risk factor, there was a very low risk of metastatic disease (0.5%) but lymph node metastases were present in eight (7%) of 116 patients. This suggests that lymphovascular invasion is an independent risk factor for nodal metastases, as is the case for early rectal cancer (see Table 10).

Findings

Lymphovascular invasion is associated with an increased risk of lymph node involvement in a malignant polyp, although lymphovascular invasion occurring without other adverse features is an unusual finding (Level IIb).

Recommendations

Lymphovascular invasion occurring in isolation carries an intermediate risk of residual cancer that should be discussed with the patient to guide discussion as to whether surgical resection of the affected segment of bowel should be removed (Grade C).

Cancer differentiation

Hamilton *et al.* [102] reported that the risk of residual disease and lymphatic metastases closely correlates with histological grading. Poor differentiation is an unusual finding in malignant polyps of the colon and rectum, being present in 4% of an early St Mark's series [110] and in 7.2% of a pooled series of 1612 malignant polyps

[14]. In Hassan's pooled study, the majority (56/380) of patients where poor differentiation was deemed to be present underwent surgical resection. The risk of lymph node metastases was 23% and the risk of metastatic spread was 10% [64]. It is generally recognized that poor differentiation in a malignant polyp is associated with a high risk of residual disease [6,69,135,149,150]. Coverlizza *et al.* [6] collated 20 patients from the literature with polyps containing poorly differentiated cancer; 10 (50%) were found to have lymph node metastases. However, poor differentiation is usually associated with other adverse histological characteristics.

Findings

Poor differentiation of cancer in a malignant polyp is an unusual finding but is associated with a high risk of residual disease in the lymph nodes. It is usually associated with other risk factors for residual disease (Level IIb).

Recommendations

Where invasive cancer in a malignant polyp is poorly differentiated, surgical resection of the affected segment of bowel should be considered, provided that the patient is fit enough to undergo such surgery (Grade B).

Combination of factors

In a number of instances, a malignant polyp will have more than one recognized risk factor for lymph node metastasis and an assessment needs to be made regarding the effect of these factors on the cumulative risk of residual disease after polypectomy. Kitajima *et al.* [130] reported lymph node metastasis in pedunculated polyps where the depth of invasion was up to 3000 μm below the muscularis mucosae only in cases where lymphatic invasion was present. Hassan *et al.* [14] also looked at combinations of risk factors. Polyps were classified into low risk ($n = 375$) where no adverse histological features were present and high risk ($n = 268$) with at least one adverse factor present (positive resection margin, lymphovascular invasion or poor differentiation). Of the 375 low-risk polyps, 295 had no surgery and local disease occurred in one patient. Eighty were treated surgically. Nodal disease was found in four. All were from one study by Colacchio *et al.* [7] containing only 39 patients. The risk of nodal metastases was therefore 0% in the other series. Metastatic disease occurred in one (0.3%) of the 375 patients. In the high-risk group, residual disease was found in 21%, recurrent disease in 9%, lymph node metastases in 11% and metastatic disease in 7%. Nivatvongs *et al.* [137] looked at a series of 151 patients with a malignant polyp who underwent polypectomy followed by bowel resection or bowel resection alone. Of these, 35 (23%) polyps had evidence of lymph

phovascular invasion, 11 (31%) of which were associated with lymph node involvement. Nevertheless, in all 11 patients, the tumour had extended to Haggitt Level 4.

Surgical resection and assessment of risk

The purpose of subjecting the patient to surgical resection following endoscopic removal of a malignant polyp is to remove the risk of progression of any residual disease. This includes excision of the draining lymph nodes. Examination of the regional lymph nodes requires diligent searching by the pathologist to identify as many lymph nodes as possible. Wasif *et al.* [12] analysed data from a large database in the USA and showed low lymph node harvests in patients undergoing surgery for a malignant polyp, with a median harvest of one node; in 49% of patients undergoing surgery, not a single node was identified. This had prognostic significance as these patients had a worse outcome than did patients in whom at least one lymph node was found and assessed. Banhaim *et al.* [172] compared lymph node harvest from 22 patients undergoing salvage colectomy after endoscopic removal of a malignant polyp with 509 patients who underwent similar resections for invasive cancer of the colon and rectum. Significantly fewer lymph nodes were retrieved in the polypectomy patients (mean = 11.63) than in patients following resection for invasive cancer (mean = 26.33).

A variety of morphological and histological features of a malignant polyp are used to assess the risk of residual disease and to group polyps into those with high, intermediate and low risk of lymph node involvement. The most important of these is whether the malignant polyp has been excised with a clear (> 1 mm) margin, followed by the depth of invasion of the tumour into the mucosa and submucosa. However, it is likely that the two are inter-related as polyps confined to Haggitt Levels 1–3 are more likely to be excised with an adequate margin compared with a polyp that extends to Level 4 or that has sessile morphology. The degree of cancer differentiation and the presence or absence of lymphovascular invasion are also prognostic indicators, but poor differentiation and lymphovascular invasion are usually seen in more deeply invasive malignant polyps. However, lymphovascular invasion occurring in the absence of any other poor prognostic indicator can occur and carries an intermediate risk of involvement of regional lymph nodes.

Polyps without adverse features (low-risk polyps) have a small likelihood of an adverse outcome [5,6,8,9,69, 110,124,130,135,136,141,149,150,152,154,156–158, 173–176] (Table 11), whereas malignant polyps with one or more high-risk features, such as poor differentia-

tion, cancer, close or involved resection margin, lymphovascular invasion or deep penetration into the submucosa, risk of residual disease reaches over 50%, depending on the number of these adverse features present [5,6,8,9,124,130,135,141,149,150,152,154,156, 157,175,176] (Table 12). Between these groups lie a number of polyps deemed to be at intermediate risk and it is these polyps that provide the greatest challenge in deciding the next course of action. Therefore, multidisciplinary team discussion is recommended in the evaluation of features that may predict residual disease and might indicate the need for surgical resection [116].

D: Surgical salvage of the high-risk polyp

Surgical decision-making for patients with no significant comorbidity and presenting with endoscopically irresectable colorectal cancer is usually straightforward. In these circumstances, unless patients have metastatic or locally advanced disease and chemotherapy or radiotherapy is proposed as neoadjuvant therapy, resection is advocated for the majority of patients, as not treating in this circumstance will usually result in disease progression. In elective cases, these decisions are agreed after discussion and review of clinical, endoscopic, histological and radiological findings at a multidisciplinary meeting [177]. Exceptions include those where comorbidity outweighs the risk of surgery, usually after anaesthetic input, or a small group of patients with rectal cancer in whom chemoradiotherapy has achieved a 'complete' response and in whom 'watchful waiting' may be considered [178]. Surgery is likely to involve, as a minimum, segmental resection of the colon and/or rectum, although in a small group of patients with 'early' rectal cancer, TEMS can be considered [179].

The increasing prevalence of the 'malignant polyp', where a polypoid cancer has been completely removed endoscopically and confirmed histologically, has presented a group of patients in whom the decision-making process to undergo further treatment is not straightforward. For many patients, polypectomy alone will be adequate and further treatment by surgery and/or chemotherapy will be unnecessary (see earlier). However, there will be a smaller group of patients with malignant polyps that have one or more adverse risk factors. It is this group of patients in whom the decision to undergo surgery for the malignant polyp or a follow-up strategy is currently unclear, and is often left to an informed 'patient choice' after review of the benefits and risks of each approach. It should be remembered that even where the risk of residual disease is assessed as being 'high', it is more likely that the resected specimen will not contain any evidence of residual disease at the

Table 11 Outcome for 'low-risk' polyps.

Number of low-risk malignant polyps	Number undergoing resection	Follow up (months)	Adverse events	Author	Date
40	3	> 60	0	Morson <i>et al.</i> [110]	1984
14	0	78 (range, 48–120)	0	Cranley <i>et al.</i> [141]	1986
70	34	> 12	0	Richards <i>et al.</i> [173]	1987
25	0	Minimum 24	0	Eckardt <i>et al.</i> [8]	1988
49	0	Mean 36	0	Rossini <i>et al.</i> [9]	1988
17	0	Range 12–56	1*	Muller <i>et al.</i> [174]	1989
67†	4	NS	0	Coverlizza <i>et al.</i> [6]	1989
7	0	69 (range, 34–96)	0	Sugihara <i>et al.</i> [175]	1989
62‡	1	> 60	3 (4.8%)	Geraghty <i>et al.</i> [176]	1991
27	14	66 (range, 12–152)	0	Kyzer <i>et al.</i> [136]	1992
47§	0	53 (range 3–119)	0	Pollard <i>et al.</i> [158]	1992
18	0	56 (range 3–117)	0	Cunningham <i>et al.</i> [154]	1994
42	0	NS	0	Hackelsberger <i>et al.</i> [150]	1995
17	0	70 (range, 43–103)	0	Volk <i>et al.</i> [156]	1995
46	NS	> 60	0	Cooper <i>et al.</i> [69]	1995
37	0	85 (range, 12–202)	0	Whitlow <i>et al.</i> [5]	1997
32	7	67 (range, 30–189)	0	Netzer <i>et al.</i> [149]	1998
41¶	NS	NS	1	Masaki & Muto [157]	2000
18	0	34 (range, 6–96)	0	Dell'Abate <i>et al.</i> [124]	2001
123**	123	NS	0	Kitajima <i>et al.</i> [130]	2004
54	5	69 (range, 9–169)	0	Seitz <i>et al.</i> [135]	2004
124	NS	17, SD = 12.9	4 (3.2%)	Gill <i>et al.</i> [152]	2013

Values are given as mean, mean and SD or median and range unless stated otherwise. NS, not stated.

*Vascular invasion present, despite complete excision in this patient.

†Low-risk criteria not defined.

‡Risk based on complete excision of malignant focus assessed endoscopically and histologically.

§Risk based on resection margin only – no assessment of lymphatic or venous invasion.

¶Polyp risk assessment based on the presence or absence of poorly differentiated or mucinous cancer at the infiltrative margin of the focus of cancer in the polyp.

**Sessile polyps with depth of invasion into submucosa < 1000 µm. Patients had been subjected to formal surgical resection of the lesion, together with draining lymph nodes.

polypectomy site or in draining lymph nodes. In a recent series, 82% of 71 patients who underwent resection after endoscopic removal of a malignant polyp did not have any evidence of residual disease in the resected specimen [152]. Other sections of this statement have considered the likelihood of mural or lymph node cancer deposits, depending on the histological or imaging features present, based on current evidence: this risk can then be applied in any given patient. This section considers the strategy that might be adopted for intermediate- or high-risk malignant polyps and reviews the risks and benefits of surgery for this cohort of patients.

In the UK, it is likely that the increase in numbers of malignant polyps being detected is a consequence of the National Bowel Cancer Screening Programme and thus many of these patients will be in the 60–74 years age group. In Scotland, the age of screening has been lowered, and thus malignant polyps are likely to be detected

in younger patients. Furthermore, malignant polyps are, and increasingly will be, resected in patients undergoing screening colonoscopy for a significant family history of colorectal cancer or surveillance postresection of cancer. This is obviously important on several counts. First, the mortality and morbidity of surgery in the younger population is considerably lower than in the older population, not only because of a lower American Society of Anesthesiology (ASA) score and comorbidity, but also as an independent variable [180]. Second, the life expectancy of a younger patient is higher. This is relevant because these patients will benefit most in terms of cancer cure if surgical treatment is required and performed. Conversely, if they were to suffer a complication of surgery, they might also have to live with the adverse consequences of surgery for a longer period of time, which might not only have greater psychological and physical consequences but also economic consequences,

Table 12 Outcome for 'high-risk' polyps.

Total number	Risk factors*	Follow up	Number high risk	Adverse outcome (%)†	Author	Date
61	PD, L/VI, IM	Minimum 24 months	36	5 (14)	Eckardt <i>et al.</i> [8]	1988
66	PD, L/VI, IM	Mean 36 months	10	4 (40)	Rossini <i>et al.</i> [9]	1988
41	PD, L/VI, IM	78 (range, 48–120)	24	10 (42)	Cranley <i>et al.</i> [141]	1986
81	PD, VI, SR, IM	NS	14	5 (36)	Coverlizza <i>et al.</i> [6]	1989
25	PD, VI, IM, DI	69 (range, 34–96)	18	3 (17)	Sugihara <i>et al.</i> [175]	1989
80	IM	> 60 months	18	2 (11)	Geraghty <i>et al.</i> [176]	1991
36	PD, L/VI, IM,	56 (range, 3–117)	16	2 (13)	Cunningham <i>et al.</i> [154]	1994
47	PD, IM	70 (range, 43–103)	30	10 (33)	Volk <i>et al.</i> [156]	1995
140	PD, L/VI, IM	> 60 months	41	14 (20)	Cooper <i>et al.</i> [69]	1995
87	PD, L/VI, IM	NS	34	7 (21)	Hackelsberger <i>et al.</i> [150]	1995
59	PD, IM, HL	85 (range, 12–202)	22	3 (14)	Whitlow <i>et al.</i> [5]	1997
70	PD, L/VI, IM	67 (range, 30–189)	38	16 (42)	Netzer <i>et al.</i> [149]	1998
75	PD, Muc, cell nests	NS	24	5 (21)	Masaki & Muto [157]	2000
27	PD, VI, IM,	34 (range, 6–96)	9‡	5 (56)	Dell'Abate <i>et al.</i> [124]	2001
865	L/VI	NA§	276	63 (22.8)	Kitajima <i>et al.</i> [130]	2004
114	PD, LI, IM	69 (range, 9–169)	60	16 (27)	Seitz <i>et al.</i> [135]	2004
209	DI¶	17, SD = 12.9	16	6 (37)	Gill <i>et al.</i> [152]	2013

Values are given as mean, mean and SD or median and range unless stated otherwise.

*Risk factors: DI, depth of invasion (into deeper submucosa); HL, Haggitt Level; IM, involved margin (in most studies < 1 mm); L/VI, lymphovascular invasion; LI, lymphatic invasion; Muc, mucinous; PD, poor differentiation; SR, signet ring; VI, vascular invasion.

†Adverse outcome includes death from colorectal cancer or residual cancer in residual specimen.

‡All nine polyps deemed to be high risk because of doubtful or involved margin.

§All patients had been subjected to formal surgical resection of lesion, together with draining lymph nodes.

¶Kikuchi sm3 or Haggitt Level 4.

particularly if the surgery were shown to be unnecessary. Similarly, surgery, as well as being of higher risk in the elderly, can often have a far greater effect on a patient's overall well-being, particularly if there were an adverse outcome [181] and, whilst many elderly patients do not work, surgery can also precipitate major social changes, such as rehousing or care-home placement. Therefore, informed patient choice really ought to concentrate not only on the likely survival benefit of surgery over conservative therapy, but also consider the potential for mortality and morbidity of surgery and the information that there may be no residual tumour in the resected specimen.

The accepted surgical principles of adequate bowel mobilization, adequate resection margins and mesocolic/TME excision, along with good anastomotic technique, should be adopted in all cases. Increasingly this surgery on otherwise normal bowel may be undertaken laparoscopically with a shorter hospital stay [182]. However, despite this, morbidity and mortality may occur.

Various methods have been used to predict peri-operative mortality, including the Physiological and Operative Severity Score (POSSUM)[183] or variations

thereof (P-POSSUM, CR-POSSUM)[184]. Laparoscopic colorectal surgery has been demonstrated to be safe, with analysis of UK Hospital Episode Statistics (HES) data revealing the 30-day in-hospital mortality to be 1.7% following laparoscopic surgery, with a significant reduction in morbidity when compared with conventional surgery [185]. A recent large series from the USA demonstrated a mortality rate of 0.3% with an anastomotic leak rate of 1.4% for laparoscopic colorectal surgery using an enhanced recovery programme [186]. The revised Association of Coloproctology of Great Britain and Ireland (ACPGBI) model has been shown to predict overall 30-day mortality to be 4% after potentially curative resectional surgery for colorectal cancer, which includes elective and emergency cases [187]. Subsequent audits in the UK in 2012 have demonstrated falls in elective colorectal resectional mortality to 2.2%, although for emergencies this figure is 7.2% (www.ic.nhs.uk/bowelreports). Thus, mortality can often be predicted, allowing at least a tailored approach to individual patients. One drawback is that current risk-adjusted data are retrospective and thus overcalls the operative mortality in many patients as it does not take into account ongoing improvements in healthcare delivery (service

centralization, access to high dependency unit or intensive care unit, improved team-working and use of minimal-access approaches). Also, these databases comprise data from patients with cancer: biologically these patients may actually behave differently from those with a malignant polyp, although this is not actually known. Recent audits on return to the operating theatre after colorectal resection have shown this to be in the range of 6–8% [188,189] and to occur for reasons including haemorrhage, wound dehiscence, anastomotic leak or stomal complications.

Other important sequelae of resection of the rectum include urinary or sexual dysfunction, particularly after low anterior resection or abdominoperineal excision of the rectum (APER) – this may be more persuasive in the younger patient for them to favour a conservative strategy, or at least TEMS, to further assess mural disease when the polyp arises in the rectum. Other negative outcomes after resection of low rectal lesions include anterior resection syndrome [190] and the potential for a permanent stoma (i.e. persisting leaks not amenable to ileostomy closure or permanent colostomy after APER). Anastomotic strictures requiring anything more than simple endoscopic balloon or dilatation at examination under anaesthetic are uncommon [191]. Local recurrence rates should be low after TME surgery or complete mesocolic excision as a result of the often early nature of this disease; however, salvage surgery, where recurrence occurs after conservative management, should be audited so that the likelihood of success in this circumstance can then be established.

Thus, despite the available evidence, the question of whether surgery is advisable with an endoscopically resected malignant polyp is determined by individual patient characteristics. The difficulties of assessing the

risk of residual disease, based on endoscopic and pathological variables, have been discussed in the section, ‘Assessing the risk of residual disease postpolypectomy’. It has, however, been established that the risk of residual disease in an individual patient can be stratified as low risk, intermediate risk or high risk. At present, low-risk patients with high-risk polyps are all usually offered surgery. In higher-risk patients, although surveillance is often likely to be undertaken, this approach needs to be tailored to the individual patient. In general, surgery is usually advised where the predicted operative mortality is lower than the risk of nodal or mural disease. However, the risk of long-term morbidity from the surgery needs to be taken into account.

E: Staging and nonendoscopic surveillance of malignant polyps

Little data exist on the role of imaging in assessment of residual mural disease, lymph node involvement or distant spread after endoscopic resection of a malignant polyp. Assessment of distant spread can be dealt with by making an assumption that the areas to be assessed and the changes looked for are similar to those in patients with established colorectal cancer: for this reason, contrast-enhanced CT would be the mainstay of assessment of distant spread, with contrast-enhanced liver MRI and positron emission tomography (PET)-CT used in specific circumstances (such as rising carcinoembryonic antigen (CEA) level in the presence of a negative CT scan).

Assessing depth of invasion

It is generally accepted that the spatial resolution of CT is too poor to allow identification of residual disease in

Table 13 Accuracy of magnetic resonance in depth of invasion (T stage) assessment of early rectal cancers.

<i>n</i>	Overall accuracy* (%)	T1 accuracy* (%)	T2 accuracy* (%)	Author	Date
38	21 (55)	2/7 (29)	2/4 (50)	Hadfield <i>et al.</i> [197]	1997
217	176 (81)	3/4 (75)	20/37 (54)	Kim <i>et al.</i> [198]	2000
49	32 (65)	1/4 (25)	3/8 (37)	Blomqvist <i>et al.</i> [192]	2000
92	70 (76)	–	6/13 (46)	Beets Tan <i>et al.</i> [201]	2001
56	48 (86)	8/10 (80)	8/10 (80)	Gagliardi <i>et al.</i> [195]	2002
36	27 (59)	6/13 (46)	6/13 (46)	Mathur <i>et al.</i> [199]	2003
98	75 (76)	2/6 (33)	13/22 (59)	Brown <i>et al.</i> [193]	2003
39	25 (64)	1/4 (25)	5/11 (45)	Fuchsjaeger <i>et al.</i> [194]	2003
42	31 (74)	–	8/13 (62)	Poon <i>et al.</i> [202]	2005
91	60 (66)	1/4 (25)	10/16 (63)	Videlhult <i>et al.</i> [200]	2007
48	46 (96)	6/6 (100)	10/12 (83)	Giutsi <i>et al.</i> [196]	2012

*Accuracy is the number of patients where the T stage, as assessed by magnetic resonance, is similar to the pathological T stage in the resected specimen and broken down for T1 and T2 tumours.

the bowel wall. Similarly, there are no data assessing the accuracy of MRI in detecting residual disease postpolypectomy, although expert radiological opinion is that an abnormality may sometimes be visible in the scar/bowel wall at the site of polypectomy. This situation differs from magnetic resonance (MR) assessment of rectal neoplasms before tumour excision (by EMR, local-excision TEMS or radical resection) where a number of studies have looked at the accuracy of T staging, which varied between 51% and 96% overall but is lower for T1 lesions – being between 25% and 100% [192–202] (Table 13). Therefore, it would appear that MRI is insufficiently accurate, in terms of reliability and reproducibility, to assess the depth of invasion of a malignant polyp before endoscopic resection, or to assess whether there is residual disease in the bowel wall postresection. No data are available on the MR assessment of residual disease or T staging in colonic neoplasms.

Turning to endoluminal ultrasound, extensive literature are available on the role of ultrasound in assessing depth of invasion (T stage) but not residual mural disease. Most of the data available relate to rectal tumours, staged using a variety of endoprobes. Since the initial studies of staging by ultrasound using a 7-MHz transducer, there has been a progressive increase in definition, with most current endorectal ultrasound scans being performed with 13-MHz transducers and endoscopic ultrasound having with transducers of 20-MHz frequency. In addition, the introduction of three-dimensional ultrasound may also increase the accuracy of endorectal ultrasound [203]. The accuracy of T staging by endorectal ultrasound varies from 55% to 91% for all stages of rectal cancer and from 25 to 98% for T1 tumours [155,194,204–210] (Table 14). However, in general use, ultrasound is not as accurate

in assessing the T stage of rectal tumours as some of the published studies suggest [211]. There are little data on ultrasound assessment of potential residual disease postpolypectomy of a malignant polyp.

Unlike current MR technology, ultrasound has the potential to assess colonic polyps before resection. Two methods of ultrasound have been described: external beam hydrocolic sonography and endoscopic ultrasonography. The former involves distending the colon with fluid to exclude gas and enable acoustic contact. Its usefulness is limited by the position of the colon in relation to the body surface and the presence of overlying gas-filled loops of bowel. Furthermore, accuracy in assessing depth of invasion is only 70% [212], which would make it unlikely to have a role in polyp staging before resection. Endoluminal endoscopic ultrasound shows more promise. For T staging, before removal of a suspicious polyp, endoscopic ultrasound has a reported accuracy of 66–93% [160,213–216]. Hurlstone *et al.* [213] showed a high level of accuracy in staging malignant polyps. Endoscopic ultrasound assessment was made of 52 Paris II sessile malignant polyps. Assessment of depth of invasion was accurate in 93% of these. All 12 Kikuchi SM1 were correctly staged, for SM2 this was 12/13 (93%) and for SM3 or greater 23/25 (93%) were correctly staged. Whether endoscopic ultrasound is more accurate than enhanced colonoscopy is contentious [160,214]. It may be possible to increase the accuracy of endoscopic ultrasound staging by submucosal injection of saline [217]. Thus, endoscopic ultrasound may have a more promising role in assessment of residual disease provided that the site of the previously removed polyp can be identified by visible scar or tattoo. Again, there are no data as yet to indicate whether endoscopic ultrasound will fulfil this role.

Table 14 Accuracy of ultrasound in assessment of depth of invasion of early rectal cancers.

n	Overall accuracy* (%)	T1 accuracy* (%)	T2 accuracy* (%)	Author	Date
160	124 (76)	43/44 (98)†	12/24 (50)	Sailer <i>et al.</i> [209]	1997
75	68 (91)	13/15 (87)	16/18 (89)	Massari <i>et al.</i> [220]	1998
154	104 (68)	36/45 (80)	40/74 (54)	Akasu <i>et al.</i> [204]	2000
378	249 (66)	49/83 (59)	104/167 (62)	Garcia Aguliar <i>et al.</i> [206]	2002
267	169 (63)	34/67 (51)	77/132 (58)	Marusch <i>et al.</i> [208]	2002
28	18 (64)	1/4 (25)	6/10 (60)	Fuchsjäger <i>et al.</i> [194]	2003
356	275 (77)	72/84 (86)	63/96 (66)	McKay <i>et al.</i> [207]	2003
44	29 (66)	22/30 (73)	7/13 (54)	Doornebosch <i>et al.</i> [155]	2008
165	91 (55)	52/91 (57)	27/56 (48)	Ashraf <i>et al.</i> [205]	2012

*Accuracy is the number of patients where the T stage, as assessed by ultrasound, is similar to the pathological T stage in the resected specimen and broken down for T1 and T2 tumours.

†Included adenomas as well as T1 cancers.

Findings

Endoscopic or endorectal ultrasound can be used to assess the depth of invasion of a malignant polyp prior to removal, but with current technology this assessment adds little to accurate endoscopic assessment using defined criteria (Level III).

Both CT and MRI are insufficiently sensitive to assess depth of invasion of a malignant polyp or residual disease in the bowel wall (Level IV).

Recommendations

Endoscopic ultrasound is not required to assess colonic polyps prior to resection. Endorectal ultrasound should be performed on all polypoid rectal tumours prior to transanal resection or open resection (Grade GP).

Assessing lymph node involvement

Perhaps of more interest in this debate is the assessment of lymph node involvement. Three imaging modalities may have a role here: CT, MR and ultrasound. CT is accepted to be of least use in decision making following excision of a malignant polyp. A number of studies have looked at lymph node assessment by MR. Lymph nodes are readily visible on MR; however, one issue that needs to be considered is variation in the criteria used to determine whether a lymph node is positive. Using size alone as a criterion for likelihood of nodal metastasis is associated with poorer accuracy, sensitivity and specific-

Table 15 Accuracy of magnetic resonance in assessing lymph node involvement in rectal cancer.

Total no.	Number node positive	Sensitivity* (%)	Accuracy† (%)	T1 accuracy† (%)	T2 accuracy† (%)	Author	Date
217	107	91/107 (85)	136/217 (69)	1/4 (25)	17/37 (46)	Kim <i>et al.</i> [198]	2000
47	12	8/12 (66)	26/47 (55)	NS	NS	Blomqvist <i>et al.</i> [192]	2000
28	12	8/12 (66)	18/26 (69)	NS	NS	Gagliardi <i>et al.</i> [195]	2002
19	Ns	NS (100)	17/19 (90)	NS	NS	Matsuoka <i>et al.</i> [220]	2003
37	16	13/16 (81)	23/37 (62)	NS	NS	Fuchsjaeger <i>et al.</i> [194]	2003
29	10	9/10 (90)	17/29 (59)	NS	NS	Ferri <i>et al.</i> [219]	2005
91	42	27/42 (64)	56/91 (62)	NS	NS	Videhult <i>et al.</i> [200]	2007
48	24	22/24 (92)	45/48 (94)	NS	NS	Giutsi <i>et al.</i> [196]	2012

*Sensitivity is the number of patients with positive lymph nodes found in the resected specimen which were identified by pre-operative magnetic resonance imaging.

†Accuracy is the number of patients where the T stage, as assessed by MRI, is similar to the pathological T stage in the resected specimen and broken down for T1 and T2 tumours

In most studies there were few patients with 'early' rectal cancer (node negative, T1 and T2 lesions). Differing criteria for identifying lymph node involvement were used.

NS, not stated.

Table 16 Accuracy of endorectal ultrasound in assessing lymph node involvement in rectal cancer.

Total no.	Number node positive	Sensitivity* (%)	Accuracy† (%)	T1 accuracy† (%)	T2 accuracy† (%)	Author	Date
154	44	24/44 (53)	111/154 (72)	71/80 (89)	41/74 (55)	Akasu <i>et al.</i> [204]	2000
120	31	NS	NS (70)	NS	NS	Placios Fanlo <i>et al.</i> [223]	2000
238	87	29/97 (33)	153/238 (64)	NS	NS	Garcia-Aguilar <i>et al.</i> [206]	2002
81	NS	NS (41)	NS 65%	NS	NS	Nesbakken <i>et al.</i> [222]	2003
263	95	64/95 (67)	215/263 (81)	NS	NS	Mackay <i>et al.</i> [207]	2003
134	47	29/47 (62)	94/134 (70)	10/21 (48)	37/44 (84)	Landmann <i>et al.</i> [221]	2007

*Sensitivity is the number of patients with positive lymph nodes found in the resected specimen which were identified by pre-operative ultrasound.

†Accuracy is the number of patients where the T stage, as assessed by ultrasound, is similar to the pathological T stage in the resected specimen and broken down for T1 and T2 tumours

Differing criteria for identifying lymph node involvement were used.

NS, not stated.

ity than when shape, contour and mixed signal intensity are included in the criteria used [218]. Accuracy of MR assessment of lymph node involvement varies from 55 to 94% [192,194–196,198,200,219,220] (Table 15), with similar variation in positive and negative predictive values. Thus, at best, the likelihood of correctly identifying whether a lymph node contains cancer is 80%. The situation is likely to be more problematic for malignant polyps (T1 lesions) where pathological studies have shown that involved lymph nodes tend to be smaller than in more advanced tumours and foci of cancer within a positive node tend to be small (< 1 mm), making them much harder to identify using current MRI techniques [221].

Similar issues beset the assessment of pericolic and perirectal lymph nodes by endoluminal ultrasound. The criteria used include size, shape and proximity to the primary tumour and echo pattern. Of these, size is the most easily measured, as shape and echo pattern are more subjective. Where the cut off in size lies between an involved and uninvolved node is important as a smaller-diameter cut off increases the sensitivity, but decreases the specificity, which would lead to patients being wrongly advised to undergo resection, where in fact they did not have nodal involvement [204]. For rectal tumours, the accuracy of endoluminal ultrasound assessment of lymph node involvement varies between 64% and 90% [204,206,207,221–223] (Table 16). For early lesions (T1), most relevant to this discussion, accuracy as high as nearly 90% has been reported. However, few of these tumours will have involved nodes, and sensitivity in this study was low (38%) as only three of eight positive lymph nodes were identified by ultrasound criteria [204]. Sensitivity for nodal involvement in T2 tumours in this study was greater, at 59%. An explanation for the low sensitivity of ultrasound in T1 tumours is provided by another study, which demonstrated increasing accuracy with advancing T stage: 48% for T1, 67% for T2 and 84% for T3 [221]. The reason for this lay in the size of lymph nodes within the mesorectum and the size of deposit in positive nodes. The median node size was 3.3 mm in T1 lesions, 6.2 mm in T2 lesions and 8.0 mm in T3 lesions. The median size of the focus of cancer within positive nodes was 0.3 mm for T1 lesions, 4.1 mm for T2 lesions and 5.9 mm for T3 lesions. Thus, for malignant polyps, relevant to this discussion, the nodes are small and when positive are likely to contain only a small focus of cancer, making them very difficult to detect on ultrasound. For colonic tumours, accuracy of endorectal ultrasound for lymph node involvement has been reported as being 85–95% in two small series [213,224]. It should be remembered

that all these studies were performed on tumours before resection, rather than on patients who were being assessed postresection, and none was performed on patients after resection of a malignant polyp.

Therefore, on the available evidence – or lack of it, CT, MRI and ultrasound are insufficiently accurate to enable a judgment to be made as to whether a visible lymph node does not contain cancer – a much harder call than when a lymph node is obviously involved.

Findings

A proportion of involved lymph nodes associated with a malignant polyp can be identified by MRI or endoluminal ultrasound. However, on available evidence (or lack of it) CT, MRI or ultrasound are not accurate enough to enable a judgment to be made as to whether a visible lymph node does not contain cancer (Level IIb).

Recommendations

Staging MRI or ultrasound scanning should not be relied on when assessing the likelihood of lymph node involvement (Grade C).

Radiological surveillance

Although no data are currently available, where ultrasound and MR may prove their value is in serial assessment by regular surveillance scans – an increase in size or a change in appearance of a node being much more significant than the appearance of an isolated scan, particularly for smaller nodes. Anecdotally, a number of units have adopted this pragmatic approach to surveillance in patients with malignant polyps at intermediate or high risk of residual disease following removal of the polyp, where a decision has been made not to perform radical resection. This is in the hope that the presence of nodal involvement becomes apparent as a stage when radical resection with curative intent is still feasible. A note of caution has to be applied here as data from series that have looked at patients followed after TEMS indicate that outcome after salvage surgery following recurrence are poor, although most of these patients were not followed with ultrasound or MR and it is likely that nodal recurrence was advanced by the time it became clinically detectable.

Concluding remarks

The management of malignant colorectal polyps remains a challenge to the colorectal multidisciplinary team because such polyps are becoming more common with the introduction of bowel cancer screening and increased use of colonoscopy in diagnosis of colorectal symptoms. Furthermore, whilst there is a large literature

Table 17 (a) Scoring the risk of residual disease following resection of a malignant polyp. (b) Risk stratification based on sum of risk factors.

(a)		Degree of Risk	
Criteria			
Resection Margin < 1 mm		++++	
Resection Margin 1–2 mm		+	
Pedunculated Haggitt level 4		++++	
Sessile: Kukuchi 2		++	
Sessile: Kukuchi 3		++++	
Poor differentiation		+++	
Mucinous tumour		+	
Tumour budding		+	
Lympho-vascular invasion		++	

(b)			
Total score	Grade of Risk	Current estimate of potential % risk of residual cancer	Recommended course of action to be discussed with patient
0	Very Low	< 3%	Routine Follow up
+	Low	< 5%	Assess other factors
++	Medium	5–10%	Careful follow up
+++	High	8–15%	Discussion of risks/benefit of surgery or follow up with patient
++++ (or more)	Very high	> 20%	Discuss risks with patient – err towards surgery Recommend surgery unless patient unfit

Criteria are based on histological description of endoscopically resected malignant polyp weighted for prognostic significance of each risk factor. Where more than one risk factor is present, the degree of risk is added together to give a total risk score.

on this subject, assessment of the risk of residual disease following endoscopic removal can be challenging. However, progress has been made, especially in the sphere of endoscopy, where, with better understanding as to how the appearance of a polyp can predict the likelihood of malignant involvement and the extent of such involvement, malignant polyps can be identified before histological assessment of a resected lesion.

It is now recognized that there are a number of features to a malignant polyp that carry prognostic significance and these should be assessed by the pathologist. How these factors combine to create an overall risk of residual disease is complex because some factors carry greater risk than others. Table 17 attempts to draw together these risk factors into a global assessment of risk of residual disease and suggested course of action to be discussed with the patient. This chart is likely to evolve with time as more data become available and the risk of residual disease becomes better defined.

Each patient with a malignant polyp needs to be considered by the colorectal cancer multidisciplinary team and an estimate of risk of residual disease should be made. The risk of residual disease is not absolute and increases with the more adverse features that are

present. By combining the various adverse features, an estimate of risk can be arrived at, which will range from low risk to very high risk. Further treatment then depends on the perceived risk of residual disease, the patient's age and general health, the morbidity and mortality risks following resection and the patient's wishes, having considered the various options, which should include postpolypectomy surveillance.

There is no doubt that it is necessary to have a better knowledge of the actual risk to a patient, in terms of nodal metastasis, recurrence and disease-specific survival, and also to assess the outcomes of surveillance, recurrence after surveillance and surgery in this increasingly large cohort of patients. To facilitate this, a national malignant polyp registry would assist a national audit – this is likely to be more ethically appropriate than a randomized controlled trial at this stage and would help to answer the question more clearly. In the future, strategies involving developed software already in use in oncological practice to illustrate decision-making analysis might also help truly inform patients and surgeons regarding not only the likely outcomes of surveillance or surgery, but also help to balance this against their individual polyp type.

Acknowledgements

The authors would like to thank Professor Pradeep Bhandari, Queen Alexandra Hospital, Portsmouth for invaluable input and Charlotte Collingridge (Medical Artist) and Peter Worledge (Medical Photographer) for Figs. 1 and 2 and Mark Smith (Medical Artist) for Figs. 3 and 4.

Contributions of authors

JGW: Design of study and overall co-ordination of project. Editing and collating sections of chapters. Input into Introduction, Risk factors for adverse outcomes, Conclusions and design of Risk Stratification (Table 17). RP: Colonoscopy section; general editing of manuscript. JH and PH: Risk factors for adverse outcome section; editing of manuscript. ES and NH: Pathology section; editing of manuscript. GB and SR: Surgical outcomes section; editing of manuscript. SMCg: Radiology section; editing of manuscript.

Conflict of interest

None declared.

References

- Williams AR, Balasooriya BA, Day DW. Polyps and cancer of the large bowel: a necropsy study in Liverpool. *Gut* 1982; **23**: 835–42.
- Morson B. President's address. The polyp-cancer sequence in the large bowel. *Proc R Soc Med* 1974; **67**(6 Pt 1): 451–7.
- Weitz J, Koch M, Debus J, Hohler T, Galle PR, Buchler MW. Colorectal cancer. *Lancet* 2005; **365**: 153–65.
- Atkin W, Cook C, Cuzick J, Edwards R, Northover J, Wardle J. Once-only flexible sigmoidoscopy screening in prevention of colorectal cancer: a multicentre randomised controlled trial. *Lancet* 2010; **375**: 1624–33.
- Whitlow C, Gathright JB Jr, Hebert SJ, Beck DE, Opelka FG, Timmcke AE, et al. Long-term survival after treatment of malignant colonic polyps. *Dis Colon Rectum* 1997; **40**: 929–34.
- Coverlizza S, Risio M, Ferrari A, Fenoglio-Preiser CM, Rossini FP. Colorectal adenomas containing invasive carcinoma. Pathologic assessment of lymph node metastatic potential. *Cancer* 1989; **64**: 1937–47.
- Colacchio TA, Forde KA, Scantlebury VP. Endoscopic polypectomy: inadequate treatment for invasive colorectal carcinoma. *Ann Surg* 1981; **194**: 704–7.
- Eckardt VF, Fuchs M, Kanzler G, Remmele W, Stienen U. Follow-up of patients with colonic polyps containing severe atypia and invasive carcinoma. Compliance, recurrence, and survival. *Cancer* 1988; **61**: 2552–7.
- Rossini FP, Ferrari A, Coverlizza S, Spandre M, Risio M, Gemme C, et al. Large bowel adenomas containing carcinoma—a diagnostic and therapeutic approach. *Int J Colorectal Dis* 1988; **3**: 47–52.
- Chapman MAS, Scholefield JH, Hardcastle JD. Management and outcome of patients with malignant colonic polyps identified from the Nottingham colo-rectal screening study. *Colorectal Dis* 2000; **2**: 8–12.
- Logan RF, Patnick J, Nickerson C, Coleman L, Rutter MD, von Wagner C. Outcomes of the Bowel Cancer Screening Programme (BCSP) in England after the first 1 million tests. *Gut* 2012; **61**: 1439–46.
- Wasif N, Etzioni D, Maggard MA, Tomlinson JS, Ko CY. Trends, patterns, and outcomes in the management of malignant colonic polyps in the general population of the United States. *Cancer* 2011; **117**: 931–7.
- Cooper HS. Surgical pathology of endoscopically removed malignant polyps of the colon and rectum. *Am J Surg Pathol* 1983; **7**: 613–23.
- Hassan C, Zullo A, Risio M, Rossini FP, Morini S. Histologic risk factors and clinical outcome in colorectal malignant polyp: a pooled-data analysis. *Dis Colon Rectum* 2005; **48**: 1588–96.
- Eccles M, Mason J. How to develop cost-conscious guidelines. *Health Technol Assess* 2001; **5**: 1–69.
- Majumdar D, Patnick J, Nickerson C, Rutter MD. Analysis of colorectal polyps detected in the english NHS bowel cancer screening programme with emphasis on advanced adenoma and polyp cancer detected. *Gut* 2012; **61**(Suppl. 2): A67.
- Cooper GS, Xu F, Barnholtz Sloan JS, Koroukian SM, Schlachter MD. Management of malignant colonic polyps: a population-based analysis of colonoscopic polypectomy versus surgery. *Cancer* 2012; **118**: 651–9.
- Bowles CJ, Leicester R, Romaya C, Swarbrick E, Williams CB, Epstein O. A prospective study of colonoscopy practice in the UK today: are we adequately prepared for national colorectal cancer screening tomorrow? *Gut* 2004; **53**: 277–83.
- Gavin DR, Valori RM, Anderson JT, Donnelly MT, Williams JG, Swarbrick ET. The national colonoscopy audit: a nationwide assessment of the quality and safety of colonoscopy in the UK. *Gut* 2013; **62**: 242–9.
- van Rijn JC, Reitsma JB, Stoker J, Bossuyt PM, van Deventer SJ, Dekker E. Polyp miss rate determined by tandem colonoscopy: a systematic review. *Am J Gastroenterol* 2006; **101**: 343–50.
- Rex DK. (2009) Missed neoplasms and optimal colonoscopic withdrawal technique. In: *Colonoscopy: Principles and Practice* (eds Waye JD, Rex DK, Williams CB), pp. 339–51. Blackwell, Oxford.
- Brenner H, Hoffmeister M, Arndt V, Stegmaier C, Altenhofen L, Haug U. Protection from right- and left-sided colorectal neoplasms after colonoscopy: population-based study. *J Natl Cancer Inst* 2010; **102**: 89–95.
- East JE, Suzuki N, Arebi N, Bassett P, Saunders BP. Position changes improve visibility during colonoscopy withdrawal: a randomized, blinded, crossover trial. *Gastrointest Endosc* 2007; **65**: 263–9.
- East JE, Bassett P, Arebi N, Thomas-Gibson S, Guenther T, Saunders BP. Dynamic patient position changes during

- colonoscopy withdrawal increase adenoma detection: a randomized, crossover trial. *Gastrointest Endosc* 2011; **73**: 456–63.
- 25 Barclay RL, Vicari JJ, Doughty AS, Johanson JF, Greenlaw RL. Colonoscopic withdrawal times and adenoma detection during screening colonoscopy. *N Engl J Med* 2006; **355**: 2533–41.
 - 26 Kaminski MF, Regula J, Kraszewska E, Polkowski M, Wojciechowska U, Didkowska J, *et al.* Quality indicators for colonoscopy and the risk of interval cancer. *N Engl J Med* 2010; **362**: 1795–803.
 - 27 Brown SR, Baraza W. Chromoscopy versus conventional endoscopy for the detection of polyps in the colon and rectum. *Cochrane Database Syst Rev* 2010; **10**: CD006439.
 - 28 Brown SR, Baraza W, Hurlstone P. Chromoscopy versus conventional endoscopy for the detection of polyps in the colon and rectum. *Cochrane Database Syst Rev* 2007; **4**: CD006439.
 - 29 Kiesslich R, von Bergh M, Hahn M, Hermann G, Jung M. Chromoendoscopy with indigocarmine improves the detection of adenomatous and nonadenomatous lesions in the colon. *Endoscopy* 2001; **33**: 1001–6.
 - 30 Rutter MD. A practical guide and review of colonoscopic surveillance and chromoendoscopy in patients with colitis. *Frontline Gastroenterol* 2010; **1**: 126–30.
 - 31 Song LM, Adler DG, Conway JD, Diehl DL, Farraye FA, Kantsevoy SV, *et al.* Narrow band imaging and multiband imaging. *Gastrointest Endosc* 2008; **67**: 581–9.
 - 32 Rex DK, Helbig CC. High yields of small and flat adenomas with high-definition colonoscopes using either white light or narrow band imaging. *Gastroenterology* 2007; **133**: 42–7.
 - 33 Adler A, Pohl H, Papanikolaou IS, Abou-Rebyeh H, Schachschal G, Veltzke-Schlieker W, *et al.* A prospective randomised study on narrow-band imaging versus conventional colonoscopy for adenoma detection: does narrow-band imaging induce a learning effect? *Gut* 2008; **57**: 59–64.
 - 34 East JE, Suzuki N, Stavrinidis M, Guenther T, Thomas HJ, Saunders BP. Narrow band imaging for colonoscopic surveillance in hereditary non-polyposis colorectal cancer. *Gut* 2008; **57**: 65–70.
 - 35 Nagorni A, Bjelakovic G, Petrovic B. Narrow band imaging versus conventional white light colonoscopy for the detection of colorectal polyps. *Cochrane Database Syst Rev* 2012; **1**: CD008361.
 - 36 Kuiper T, van den Broek FJ, Naber AH, van Soest EJ, Scholten P, Mallant-Hent R, *et al.* Endoscopic trimodal imaging detects colonic neoplasia as well as standard video endoscopy. *Gastroenterology* 2011; **140**: 1887–94.
 - 37 Ignjatovic A, Thomas-Gibson S, East JE, Haycock A, Bassett P, Bhandari P, *et al.* Development and validation of a training module on the use of narrow-band imaging in differentiation of small adenomas from hyperplastic colorectal polyps. *Gastrointest Endosc* 2011; **73**: 128–33.
 - 38 Westwood DA, Alexakis N, Connor SJ. Transparent cap-assisted colonoscopy versus standard adult colonoscopy: a systematic review and meta-analysis. *Dis Colon Rectum* 2012; **55**: 218–25.
 - 39 Roy HK, Goldberg MJ, Bajaj S, Backman V. Colonoscopy and optical biopsy: bridging technological advances to clinical practice. *Gastroenterology* 2011; **140**: 1863–7.
 - 40 Nusko G, Mansmann U, Partzsch U, Altendorf-Hofmann A, Groitl H, Wittekind C, *et al.* Invasive carcinoma in colorectal adenomas: multivariate analysis of patient and adenoma characteristics. *Endoscopy* 1997a; **29**: 626–31.
 - 41 Nusko G, Mansmann U, Altendorf-Hofmann A, Groitl H, Wittekind C, Hahn EG. Risk of invasive carcinoma in colorectal adenomas assessed by size and site. *Int J Colorectal Dis* 1997b; **12**: 267–71.
 - 42 Williams CB, Whiteway JE, Jass JR. Practical aspects of endoscopic management of malignant polyps. *Endoscopy* 1987; **19**(Suppl. 1): 31–7.
 - 43 Koyama Y, Kotake K. Overview of colorectal cancer in Japan: report from the Registry of the Japanese Society for Cancer of the Colon and Rectum. *Dis Colon Rectum* 1997; **40**(Suppl. 10): S2–9.
 - 44 Kudo S. Endoscopic mucosal resection of flat and depressed types of early colorectal cancer. *Endoscopy* 1993; **25**: 455–61.
 - 45 Participants in the Paris Workshop. The Paris endoscopic classification of superficial neoplastic lesions: esophagus, stomach, and colon: November 30 to December 1, 2002. *Gastrointest Endosc* 2003; **58**(Suppl. 6): S3–43.
 - 46 Endoscopic Classification Review Group. Update on the paris classification of superficial neoplastic lesions in the digestive tract. *Endoscopy* 2005; **37**: 570–8.
 - 47 Uraoka T, Saito Y, Matsuda T, Ikehara H, Gotoda T, Saito D, *et al.* Endoscopic indications for endoscopic mucosal resection of laterally spreading tumours in the colorectum. *Gut* 2006; **55**: 1592–7.
 - 48 Saitoh Y, Obara T, Watari J, Nomura M, Taruishi M, Orii Y, *et al.* Invasion depth diagnosis of depressed type early colorectal cancers by combined use of videoendoscopy and chromoendoscopy. *Gastrointest Endosc* 1998; **48**: 362–70.
 - 49 Rembacken BJ, Fujii T, Cairns A, Dixon MF, Yoshida S, Chalmers DM, *et al.* Flat and depressed colonic neoplasms: a prospective study of 1000 colonoscopies in the UK. *Lancet* 2000; **355**: 1211–4.
 - 50 Suzuki N, Talbot IC, Saunders BP. The prevalence of small, flat colorectal cancers in a western population. *Colorectal Dis* 2004; **6**: 15–20.
 - 51 Kudo S, Tamura S, Nakajima T, Yamano H, Kusaka H, Watanabe H. Diagnosis of colorectal tumorous lesions by magnifying endoscopy. *Gastrointest Endosc* 1996; **44**: 8–14.
 - 52 Kashida H, Kudo SE. Early colorectal cancer: concept, diagnosis, and management. *Int J Clin Oncol* 2006; **11**: 1–8.
 - 53 Wu L, Li Y, Li Z, Cao Y, Gao F. Diagnostic accuracy of narrow-band imaging for the differentiation of neoplastic from non-neoplastic colorectal polyps: a meta-analysis. *Colorectal Dis* 2013; **15**: 3–11.
 - 54 Katagiri A, Fu KI, Sano Y, Ikematsu H, Horimatsu T, Kaneko K, *et al.* Narrow band imaging with magnifying

- colonoscopy as diagnostic tool for predicting histology of early colorectal neoplasia. *Aliment Pharmacol Ther* 2008; **27**: 1269–74.
- 55 Sano Y, Emura F, Ikematsu H. (2009 2nd edition) Narrow band Imaging. In: *Colonoscopy: Principles and Practice* (eds Waye JD, Rex DK, Williams CB), pp. 514–526. Blackwell, Oxford.
 - 56 Yoshida N, Naito Y, Kugai M, Inoue K, Uchiyama K, Takagi T, *et al.* Efficacy of magnifying endoscopy with flexible spectral imaging color enhancement in the diagnosis of colorectal tumors. *J Gastroenterol* 2011; **46**: 65–72.
 - 57 Yoshida N, Naito Y, Inada Y, Kugai M, Inoue K, Uchiyama K, *et al.* The detection of surface patterns by flexible spectral imaging color enhancement without magnification for diagnosis of colorectal polyps. *Int J Colorectal Dis* 2012; **27**: 605–11.
 - 58 Longcroft-Wheaton GR, Higgins B, Bhandari P. Flexible spectral imaging color enhancement and indigo carmine in neoplasia diagnosis during colonoscopy: a large prospective UK series. *Eur J Gastroenterol Hepatol* 2011; **23**: 903–11.
 - 59 Su P, Liu Y, Lin S, Xiao K, Chen P, An S, *et al.* Efficacy of confocal laser endomicroscopy for discriminating colorectal neoplasms from non-neoplasms: a systematic review and meta-analysis. *Colorectal Dis* 2013; **15**: e1–12.
 - 60 Kodashima S, Fujishiro M. Novel image-enhanced endoscopy with i-scan technology. *World J Gastroenterol* 2010; **16**: 1043–9.
 - 61 Uno Y, Munakata A. The non-lifting sign of invasive colon cancer. *Gastrointest Endosc* 1994; **40**: 485–9.
 - 62 Ishiguro A, Uno Y, Ishiguro Y, Munakata A, Morita T. Correlation of lifting versus non-lifting and microscopic depth of invasion in early colorectal cancer. *Gastrointest Endosc* 1999; **50**: 329–33.
 - 63 Kobayashi N, Saito Y, Sano Y, Urugami N, Michita T, Nasu J, *et al.* Determining the treatment strategy for colorectal neoplastic lesions: endoscopic assessment or the non-lifting sign for diagnosing invasion depth? *Endoscopy* 2007; **39**: 701–5.
 - 64 Moss A, Bourke MJ, Williams SJ, Hourigan LF, Brown G, Tam W, *et al.* Endoscopic mucosal resection outcomes and prediction of submucosal cancer from advanced colonic mucosal neoplasia. *Gastroenterology* 2011; **140**: 1909–18.
 - 65 Voloyiannis T, Snyder MJ, Bailey RR, Pidala M. Management of the difficult colon polyp referred for resection: resect or rescope? *Dis Colon Rectum* 2008; **51**: 292–5.
 - 66 Swan MP, Bourke MJ, Alexander S, Moss A, Williams SJ. Large refractory colonic polyps: is it time to change our practice? A prospective study of the clinical and economic impact of a tertiary referral colonic mucosal resection and polypectomy service (with videos). *Gastrointest Endosc* 2009; **70**: 1128–36.
 - 67 Williams CB, Saunders BP, Talbot IC. Endoscopic management of polypoid early colon cancer. *World J Surg* 2000; **24**: 1047–51.
 - 68 Doniec JM, Lohnert MS, Schniewind B, Bokelmann F, Kremer B, Grimm H. Endoscopic removal of large colonic polyps: prevention of unnecessary surgery? *Dis Colon Rectum* 2003; **46**: 340–8.
 - 69 Cooper HS, Deppisch LM, Gourley WK, Kahn EI, Lev R, Manley PN, *et al.* Endoscopically removed malignant colorectal polyps: clinicopathologic correlations. *Gastroenterology* 1995; **108**: 1657–65.
 - 70 Repici A, Pellicano R, Strangio G, Danese S, Fagoonee S, Malesci A. Endoscopic mucosal resection for early colorectal neoplasia: pathologic basis, procedures, and outcomes. *Dis Colon Rectum* 2009; **52**: 1502–15.
 - 71 Waye JD. (2009) Polypectomy – basic principles. In: *Colonoscopy: Principles and Practice* (eds Waye JD, Rex DK, Williams CB), pp. 410–20. Blackwell, Oxford.
 - 72 Brooker JC, Saunders BP, Shah SG, Thapar CJ, Suzuki N, Williams CB. Treatment with argon plasma coagulation reduces recurrence after piecemeal resection of large sessile colonic polyps: a randomized trial and recommendations. *Gastrointest Endosc* 2002; **55**: 371–5.
 - 73 Zlatanovic J, Waye JD, Kim PS, Baiocco PJ, Gleim GW. Large sessile colonic adenomas: use of argon plasma coagulator to supplement piecemeal snare polypectomy. *Gastrointest Endosc* 1999; **49**: 731–5.
 - 74 Puli SR, Kakugawa Y, Saito Y, Antillon D, Gotoda T, Antillon MR. Successful complete cure en-bloc resection of large nonpedunculated colonic polyps by endoscopic submucosal dissection: a meta-analysis and systematic review. *Ann Surg Oncol* 2009; **16**: 2147–51.
 - 75 Yahagi N (2009 2nd edition) Endoscopic submucosal dissection in the colon. In: *Colonoscopy: Principles and Practice* (eds Waye JD, Rex DK, Williams CB), pp. 603–12. Blackwell, Oxford.
 - 76 Saito Y, Matsuda T, Fujii T. Endoscopic submucosal dissection of non-polypoid colorectal neoplasms. *Gastrointest Endosc Clin N Am* 2010; **20**: 515–24.
 - 77 Kantsevoy SV, Adler DG, Conway JD, Diehl DL, Farrar FA, Kwon R, *et al.* Endoscopic mucosal resection and endoscopic submucosal dissection. *Gastrointest Endosc* 2008; **68**: 11–8.
 - 78 Deprez PH, Bergman JJ, Meisner S, Ponchon T, Repici A, Dinis-Ribeiro M, *et al.* Current practice with endoscopic submucosal dissection in Europe: position statement from a panel of experts. *Endoscopy* 2010; **42**: 853–8.
 - 79 Probst A, Golger D, Anthuber M, Markl B, Messmann H. Endoscopic submucosal dissection in large sessile lesions of the rectosigmoid: learning curve in a European center. *Endoscopy* 2012; **44**: 660–7.
 - 80 Gavin DR, Valori RM, Anderson JT, Donnelly MT, Williams JG, Swarbrick ET. The national colonoscopy audit: a nationwide assessment of the quality and safety of colonoscopy in the UK. *Gut* 2013; **62**: 242–49.
 - 81 Heldwein W, Dollhopf M, Rosch T, Meining A, Schmidtsdorff G, Hasford J, *et al.* The Munich Polypectomy Study (MUPS): prospective analysis of complications and risk factors in 4000 colonic snare polypectomies. *Endoscopy* 2005; **37**: 1116–22.

- 82 Ginsberg GG, Barkun AN, Bosco JJ, Burdick JS, Isenberg GA, Nakao NL, *et al.* The argon plasma coagulator: February 2002. *Gastrointest Endosc* 2002; **55**: 807–10.
- 83 Zafar A, Mustafa M, Chapman M. Colorectal polyps: when should we tattoo? *Surg Endosc* 2012; **26**: 3264–6.
- 84 Conaghan PJ, Maxwell-Armstrong CA, Garrioch MV, Hong L, Acheson AG. Leaving a mark: the frequency and accuracy of tattooing prior to laparoscopic colorectal surgery. *Colorectal Dis* 2011; **13**: 1184–7.
- 85 Askin MP, Waye JD, Fiedler L, Harpaz N. Tattoo of colonic neoplasms in 113 patients with a new sterile carbon compound. *Gastrointest Endosc* 2002; **56**: 339–42.
- 86 Cho YB, Lee WY, Yun HR, Lee WS, Yun SH, Chun HK. Tumor localization for laparoscopic colorectal surgery. *World J Surg* 2007; **31**: 1491–5.
- 87 Cairns S, Scholefield JH. Guidelines for colorectal cancer screening in high risk groups. *Gut* 2002; **51**(Suppl. 5): V1–2.
- 88 Cairns SR, Scholefield JH, Steele RJ, Dunlop MG, Thomas HJ, Evans GD, *et al.* Guidelines for colorectal cancer screening and surveillance in moderate and high risk groups (update from 2002). *Gut* 2010; **59**: 666–89.
- 89 Rex DK, Kahi CJ, Levin B, Smith RA, Bond JH, Brooks D, *et al.* Guidelines for colonoscopy surveillance after cancer resection: a consensus update by the American Cancer Society and the US Multi-Society Task Force on Colorectal Cancer. *Gastroenterology* 2006; **130**: 1865–71.
- 90 Seo GJ, Sohn DK, Han KS, Hong CW, Kim BC, Park JW, *et al.* Recurrence after endoscopic piecemeal mucosal resection for large sessile colorectal polyps. *World J Gastroenterol* 2010; **16**: 2806–11.
- 91 Winawer SJ, Zauber AG, Fletcher RH, Stillman JS, O'Brien MJ, Levin B, *et al.* Guidelines for colonoscopy surveillance after polypectomy: a consensus update by the US Multi-Society Task Force on Colorectal Cancer and the American Cancer Society. *Gastroenterology* 2006; **130**: 1872–85.
- 92 Lieberman DA, Rex DK, Winawer SJ, Giardiello FM, Johnson DA, Levin TR. Guidelines for colonoscopy surveillance after screening and polypectomy: a consensus update by the US Multi-Society Task Force on Colorectal Cancer. *Gastroenterology* 2012; **143**: 844–57.
- 93 Ahlawat SK, Gupta N, Benjamin SB, Al-Kawas FH. Large colorectal polyps: endoscopic management and rate of malignancy: does size matter? *J Clin Gastroenterol* 2011; **45**: 347–54.
- 94 Martinez ME, Baron JA, Lieberman DA, Schatzkin A, Lanza E, Winawer SJ, *et al.* A pooled analysis of advanced colorectal neoplasia diagnoses after colonoscopic polypectomy. *Gastroenterology* 2009; **136**: 832–41.
- 95 Schlemper RJ. The Vienna classification of gastrointestinal epithelial neoplasia. *Gut* 2000; **47**: 251–5.
- 96 Quirke P, Carey F, Newbold M, Shepherd N, Warren B, Williams G. (2007) *Reporting Lesions in the NHS Bowel Cancer Screening Programme*. NHS BCSP publication, Sheffield. Available from: <http://www.cancerscreening.nhs.uk/bowel/publications/nhsbcsp01.pdf> (accessed March 2011).
- 97 Bond JH. Polyp guideline: diagnosis, treatment, and surveillance for patients with colorectal polyps. Practice Parameters Committee of the American College of Gastroenterology. *Am J Gastroenterol* 2000; **95**: 3053–63.
- 98 Morson BC. Factors influencing the prognosis of early cancer of the rectum. *Proc R Soc Med* 1966; **59**: 607–8.
- 99 Heitman SJ, Ronksley PE, Hilsden RJ, Manns BJ, Rostom A, Hemmelgarn BR. Prevalence of adenomas and colorectal cancer in average risk individuals: a systematic review and meta-analysis. *Clin Gastroenterol Hepatol* 2009; **7**: 1272–8.
- 100 Strul H, Kariv R, Leshno M, Halak A, Jakubowicz M, Santo M, *et al.* The prevalence rate and anatomic location of colorectal adenoma and cancer detected by colonoscopy in average-risk individuals aged 40–80 years. *Am J Gastroenterol* 2006; **101**: 255–62.
- 101 Quirke P, Morris E. Reporting colorectal cancer. *Histopathology* 2007; **50**: 103–12.
- 102 Hamilton ST, Rubio CA, Vogelstein B. (2000) Carcinoma of the colon and rectum. In: *Pathology and Genetics Tumours of the Digestive System* (eds Hamilton S, Aaltonen LA), pp. 111–2. World Health Organisation Classification of Tumours, IARC Press, Lyon, France.
- 103 Hunter J, Harmston C, Hughes P, Wong L. What is the nature of polyps detected by the NHS bowel cancer screening pilots? *Colorectal Dis* 2011; **13**: 538–41.
- 104 Harrow P, Nayagam N, Stafford K, Hopkins K, Loak R. A comparison of incidence of colorectal cancer and polyps in bowel cancer screening programme patients with symptomatic patients referred under 2 week wait in a demographically matched population. *Gut* 2011; **60**: A114.
- 105 Ekelund G, Lindstrom C. Histopathological analysis of benign polyps in patients with carcinoma of the colon and rectum. *Gut* 1974; **15**: 654–63.
- 106 Konishi F, Morson BC. Pathology of colorectal adenomas: a colonoscopic survey. *J Clin Pathol* 1982; **35**: 830–41.
- 107 Riddell RH, Goldman H, Ransohoff DF, Appelman HD, Fenoglio CM, Haggitt RC, *et al.* Dysplasia in inflammatory bowel disease: standardized classification with provisional clinical applications. *Hum Pathol* 1983; **14**: 931–68.
- 108 Foss F, West K, McGregor A. Pathology of polyps detected in the bowel cancer screening programme. *Diagn Histopathol* 2011; **17**: 495–504.
- 109 Lipper S, Kahn LB, Ackerman LV. The significance of microscopic invasive cancer in endoscopically removed polyps of the large bowel. A clinicopathologic study of 51 cases. *Cancer* 1983; **52**: 1691–9.
- 110 Morson BC, Whiteway JE, Jones EA, Macrae FA, Williams CB. Histopathology and prognosis of malignant colorectal polyps treated by endoscopic polypectomy. *Gut* 1984; **25**: 437–44.
- 111 Edge S, Byrd D, Compton C, Fritz A, Greene F, Trotti A. (2010 7th edition) *AJCC Cancer Staging Manual*. Springer-Verlag, New York, NY.

- 112 Fenoglio CM, Pascal RR. Colorectal adenomas and cancer: pathologic relationships. *Cancer* 1982; **50**(Suppl. 11): 2601–8.
- 113 Bretagne JF, Manfredi S, Piette C, Hamonic S, Durand G, Riou F. Yield of high-grade dysplasia based on polyp size detected at colonoscopy: a series of 2295 examinations following a positive fecal occult blood test in a population-based study. *Dis Colon Rectum* 2010; **53**: 339–45.
- 114 Lieberman D, Moravec M, Holub J. Polyp size and advancing histology in patients undergoing colonoscopy screening: implications for CT colonography. *Gastroenterology* 2008; **135**: 1100–5.
- 115 Muto T, Bussey HJ, Morson BC. The evolution of cancer of the colon and rectum. *Cancer* 1975; **36**: 2251–70.
- 116 Quirke P, Risio M, Lambert R, von Karsa L, Vieth M. Quality assurance in pathology in colorectal cancer screening and diagnosis-European recommendations. *Virchows Arch* 2011; **458**: 1–19.
- 117 Jass J, Whitehall V, Young J, Leggett B. Emerging concepts in colorectal neoplasia. *Gastroenterology* 2001; **123**: 862–76.
- 118 Jass JR, Stewart SM. Evolution of hereditary non-polypoid colorectal cancer. *Gut* 1992; **33**: 783–6.
- 119 Jass JR, Young J, Leggett BA. Hyperplastic polyps and DNA microsatellite unstable cancers of the colorectum. *Histopathology* 2000; **37**: 295–301.
- 120 Longacre TA, Fenoglio-Preiser CM. Mixed hyperplastic adenomatous polyps/serrated adenomas. A distinct form of colorectal neoplasia. *Am J Surg Pathol* 1990; **14**: 524–37.
- 121 Ensari A, Bosman FT, Offerhaus GJ. The serrated polyp: getting it right! *J Clin Pathol* 2010; **63**: 665–8.
- 122 Snover D, Burt R, Odze R. (2010 4th edition) Serrated polyps of the colon and rectum and serrated polyposis. In: *WHO Classification of Tumours of the Digestive System* (eds Bosman FT, Carneiro F, Hruban RH, Theise ND), IARC Press, Lyon.
- 123 Vu HT, Lopez R, Bennett A, Burke CA. Individuals with sessile serrated polyps express an aggressive colorectal phenotype. *Dis Colon Rectum* 2011; **54**: 1216–23.
- 124 Dell'Abate P, Iosca A, Galimberti A, Piccolo P, Soliani P, Foggi E. Endoscopic treatment of colorectal benign-appearing lesions 3 cm or larger: techniques and outcome. *Dis Colon Rectum* 2001; **44**: 112–8.
- 125 Christoforidis D, Cho HM, Dixon MR, Mellgren AF, Madoff RD, Finne CO. Transanal endoscopic microsurgery versus conventional transanal excision for patients with early rectal cancer. *Ann Surg* 2009; **249**: 776–82.
- 126 Middleton PF, Sutherland LM, Maddern GJ. Transanal endoscopic microsurgery: a systematic review. *Dis Colon Rectum* 2005; **48**: 270–84.
- 127 Bach SP, Hill J, Monson JR, Simson JN, Lane L, Merrie A, et al. A predictive model for local recurrence after transanal endoscopic microsurgery for rectal cancer. *Br J Surg* 2009; **96**: 280–90.
- 128 Haggitt RC, Glotzbach RE, Soffer EE, Wruble LD. Prognostic factors in colorectal carcinomas arising in adenomas: implications for lesions removed by endoscopic polypectomy. *Gastroenterology* 1985; **89**: 328–36.
- 129 Kikuchi R, Takano M, Takagi K, Fujimoto N, Nozaki R, Fujiyoshi T, et al. Management of early invasive colorectal cancer. Risk of recurrence and clinical guidelines. *Dis Colon Rectum* 1995; **38**: 1286–95.
- 130 Kitajima K, Fujimori T, Fujii S, Takeda J, Ohkura Y, Kawamata H, et al. Correlations between lymph node metastasis and depth of submucosal invasion in submucosal invasive colorectal carcinoma: a Japanese collaborative study. *J Gastroenterol* 2004; **39**: 534–43.
- 131 Ueno H, Mochizuki H, Hashiguchi Y, Shimazaki H, Aida S, Hase K, et al. Risk factors for an adverse outcome in early invasive colorectal carcinoma. *Gastroenterology* 2004; **127**: 385–94.
- 132 Bujanda L, Cosme A, Gil I, Arenas-Mirave JL. Malignant colorectal polyps. *World J Gastroenterol* 2010; **16**: 3103–11.
- 133 Robert ME. The malignant colon polyp: diagnosis and therapeutic recommendations. *Clin Gastroenterol Hepatol* 2007; **5**: 662–7.
- 134 Netzer P, Binek J, Hammer B, Lange J, Schmassmann A. Significance of histologic criteria for the management of patients with malignant colorectal polyps and polypectomy. *Scand J Gastroenterol* 1997; **32**: 910–6.
- 135 Seitz U, Bohnacker S, Seewald S, Thonke F, Brand B, Brautigan T, et al. Is endoscopic polypectomy an adequate therapy for malignant colorectal adenomas? Presentation of 114 patients and review of the literature. *Dis Colon Rectum* 2004; **47**: 1789–96; discussion 96–7.
- 136 Kyzer S, Begin LR, Gordon PH, Mitmaker B. The care of patients with colorectal polyps that contain invasive adenocarcinoma. Endoscopic polypectomy or colectomy? *Cancer* 1992; **70**: 2044–50.
- 137 Nivatvongs S, Rojanasakul A, Reiman HM, Dozois RR, Wolff BG, Pemberton JH, et al. The risk of lymph node metastasis in colorectal polyps with invasive adenocarcinoma. *Dis Colon Rectum* 1991; **34**: 323–8.
- 138 Kaneko I, Tanaka S, Oka S, Kawamura T, Hiyama T, Ito M, et al. Lymphatic vessel density at the site of deepest penetration as a predictor of lymph node metastasis in submucosal colorectal cancer. *Dis Colon Rectum* 2007; **50**: 13–21.
- 139 Masaki T, Goto A, Sugiyama M, Matsuoka H, Abe N, Sakamoto A, et al. Possible contribution of CD44 variant 6 and nuclear beta-catenin expression to the formation of budding tumor cells in patients with T1 colorectal carcinoma. *Cancer* 2001; **92**: 2539–46.
- 140 Egashira Y, Yoshida T, Hirata I, Hamamoto N, Akutagawa H, Takeshita A, et al. Analysis of pathological risk factors for lymph node metastasis of submucosal invasive colon cancer. *Mod Pathol* 2004; **17**: 503–11.
- 141 Cranley JP, Petras RE, Carey WD, Paradis K, Sivak MV. When is endoscopic polypectomy adequate therapy for colonic polyps containing invasive carcinoma? *Gastroenterology* 1986; **91**: 419–27.

- 142 Cooper HS, Deppisch LM, Kahn EI, Lev R, Manley PN, Pascal RR, *et al.* Pathology of the malignant colorectal polyp. *Hum Pathol* 1998; **29**: 15–26.
- 143 Komuta K, Batts K, Jessurun J, Snover D, Garcia-Aguilar J, Rothenberger D, *et al.* Interobserver variability in the pathological assessment of malignant colorectal polyps. *Br J Surg* 2004; **91**: 1479–84.
- 144 van Putten PG, Hol L, van Dekken H, Han van Krieken J, van Ballegooijen M, Kuipers EJ, *et al.* Inter-observer variation in the histological diagnosis of polyps in colorectal cancer screening. *Histopathology* 2011; **58**: 974–81.
- 145 Mitchell PJ, Haboubi NY. The malignant adenoma: when to operate and when to watch. *Surg Endosc* 2008; **22**: 1563–9.
- 146 Haboubi N. (2002) Preparation and processing of Polyps. In: *Gastrointestinal Polyps* (eds Haboubi N, Shepherd N, Geobes K), pp. 161–165. GMM, London.
- 147 Morson B, Dawson I, Day D. (1990) Reception and examination of biopsy and surgical specimen. In: *Gastrointestinal Pathology* (eds Morson B, Dawson I), pp. 3–7. Blackwell Scientific Publications, Oxford.
- 148 Absar MS, Haboubi NY. Colonic neoplastic polyps: biopsy is not efficient to exclude malignancy. The Trafford experience. *Tech Coloproctol* 2004; **8**(Suppl. 2): s257–60.
- 149 Netzer P, Forster C, Biral R, Ruchti C, Neuweiler J, Stauffer E, *et al.* Risk factor assessment of endoscopically removed malignant colorectal polyps. *Gut* 1998; **43**: 669–74.
- 150 Hackelsberger A, Fruhmorgen P, Weiler H, Heller T, Seeliger H, Junghanns K. Endoscopic polypectomy and management of colorectal adenomas with invasive carcinoma. *Endoscopy* 1995; **27**: 153–8.
- 151 Boenicke L, Fein M, Sailer M, Isbert C, Germer CT, Thalheimer A. The concurrence of histologically positive resection margins and sessile morphology is an important risk factor for lymph node metastasis after complete endoscopic removal of malignant colorectal polyps. *Int J Colorectal Dis* 2010; **25**: 433–8.
- 152 Gill MD, Rutter MD, Holtham SJ. Management and short-term outcome of malignant colorectal polyps in the north of England (1). *Colorectal Dis* 2013; **15**: 169–76.
- 153 Borschitz T, Gockel I, Kiesslich R, Junginger T. Oncological outcome after local excision of rectal carcinomas. *Ann Surg Oncol* 2008a; **15**: 3101–8.
- 154 Cunningham KN, Mills LR, Schuman BM, Mwakyusa DH. Long-term prognosis of well-differentiated adenocarcinoma in endoscopically removed colorectal adenomas. *Dig Dis Sci* 1994; **39**: 2034–7.
- 155 Doornebosch PG, Tollenaar RA, De Graaf EJ. Is the increasing role of Transanal Endoscopic Microsurgery in curation for T1 rectal cancer justified? A systematic review. *Acta Oncol* 2009; **48**: 343–53.
- 156 Volk EE, Goldblum JR, Petras RE, Carey WD, Fazio VW. Management and outcome of patients with invasive carcinoma arising in colorectal polyps. *Gastroenterology* 1995; **109**: 1801–7.
- 157 Masaki T, Muto T. Predictive value of histology at the invasive margin in the prognosis of early invasive colorectal carcinoma. *J Gastroenterol* 2000; **35**: 195–200.
- 158 Pollard CW, Nivatvongs S, Rojanasakul A, Reiman HM, Dozois RR. The fate of patients following polypectomy alone for polyps containing invasive carcinoma. *Dis Colon Rectum* 1992; **35**: 933–7.
- 159 Nascimbeni R, Burgart LJ, Nivatvongs S, Larson DR. Risk of lymph node metastasis in T1 carcinoma of the colon and rectum. *Dis Colon Rectum* 2002; **45**: 200–6.
- 160 Matsuda T, Fukuzawa M, Uraoka T, Nishi M, Yamaguchi Y, Kobayashi N, *et al.* Risk of lymph node metastasis in patients with pedunculated type early invasive colorectal cancer: a retrospective multicenter study. *Cancer Sci* 2011; **102**: 1693–7.
- 161 Park YJ, Kim WH, Paeng SS, Park JG. Histoclinical analysis of early colorectal cancer. *World J Surg* 2000; **24**: 1029–35.
- 162 Kim MN, Kang JM, Yang JI, Kim BK, Im JP, Kim SG, *et al.* Clinical features and prognosis of early colorectal cancer treated by endoscopic mucosal resection. *J Gastroenterol Hepatol* 2011; **26**: 1619–25.
- 163 Borschitz T, Heintz A, Junginger T. The influence of histopathologic criteria on the long-term prognosis of locally excised pT1 rectal carcinomas: results of local excision (transanal endoscopic microsurgery) and immediate reoperation. *Dis Colon Rectum* 2006; **49**: 1492–506; discussion 500–5.
- 164 Buess G, Mentges B, Manncke K, Starlinger M, Becker HD. Technique and results of transanal endoscopic microsurgery in early rectal cancer. *Am J Surg* 1992; **163**: 63–9; discussion 9–70.
- 165 Winde G, Nottberg H, Keller R, Schmid KW, Bunte H. Surgical cure for early rectal carcinomas (T1). Transanal endoscopic microsurgery vs. anterior resection. *Dis Colon Rectum* 1996; **39**: 969–76.
- 166 Endreseth BH, Myrvold HE, Romundstad P, Hestvik UE, Bjerkeset T, Wibe A. Transanal excision vs. major surgery for T1 rectal cancer. *Dis Colon Rectum* 2005; **48**: 1380–8.
- 167 Bentrem DJ, Okabe S, Wong WD, Guillem JG, Weiser MR, Temple LK, *et al.* T1 adenocarcinoma of the rectum: transanal excision or radical surgery? *Ann Surg* 2005; **242**: 472–7; discussion 7–9.
- 168 Peeters KC, Marijnen CA, Nagtegaal ID, Kranenbarg EK, Putter H, Wiggers T, *et al.* The TME trial after a median follow-up of 6 years: increased local control but no survival benefit in irradiated patients with resectable rectal carcinoma. *Ann Surg* 2007; **246**: 693–701.
- 169 Lezoche G, Baldarelli M, Guerrieri M, Paganini AM, De Sanctis A, Bartolacci S, *et al.* A prospective randomized study with a 5-year minimum follow-up evaluation of transanal endoscopic microsurgery versus laparoscopic total mesorectal excision after neoadjuvant therapy. *Surg Endosc* 2008; **22**: 352–8.
- 170 Borschitz T, Wachtlin D, Mohler M, Schmidberger H, Junginger T. Neoadjuvant chemoradiation and local exci-

- sion for T2-3 rectal cancer. *Ann Surg Oncol* 2008b; **15**: 712–20.
- 171 Smith FM, Waldron D, Winter DC. Rectum-conserving surgery in the era of chemoradiotherapy. *Br J Surg* 2010; **97**: 1752–64.
 - 172 Benhaim L, Benoist S, Bachet JB, Julie C, Penna C, Nordlinger B. Salvage colectomy for endoscopically-removed malignant colon polyps: is it possible to determine the optimal number of lymph nodes that need to be harvested? *Colorectal Dis* 2012; **14**: 79–88.
 - 173 Richards WO, Webb WA, Morris SJ, Davis RC, McDaniel L, Jones L, *et al.* Patient management after endoscopic removal of the cancerous colon adenoma. *Ann Surg* 1987; **205**: 665–72.
 - 174 Muller S, Chesner IM, Egan MJ, Rowlands DC, Collard MJ, Swarbrick ET, *et al.* Significance of venous and lymphatic invasion in malignant polyps of the colon and rectum. *Gut* 1989; **30**: 1385–91.
 - 175 Sugihara K, Muto T, Morioka Y. Management of patients with invasive carcinoma removed by colonoscopic polypectomy. *Dis Colon Rectum* 1989; **32**: 829–34.
 - 176 Geraghty JM, Williams CB, Talbot IC. Malignant colorectal polyps: venous invasion and successful treatment by endoscopic polypectomy. *Gut* 1991; **32**: 774–8.
 - 177 MacDermid E, Hooton G, MacDonald M, McKay G, Grose D, Mohammed N, *et al.* Improving patient survival with the colorectal cancer multi-disciplinary team. *Colorectal Dis* 2009; **11**: 291–5.
 - 178 Glynn-Jones R, Hughes R. Critical appraisal of the 'wait and see' approach in rectal cancer for clinical complete responders after chemoradiation. *Br J Surg* 2012; **99**: 897–909.
 - 179 Neary P, Makin GB, White TJ, White E, Hartley J, MacDonald A, *et al.* Transanal endoscopic microsurgery: a viable operative alternative in selected patients with rectal lesions. *Ann Surg Oncol* 2003; **10**: 1106–11.
 - 180 Tan E, Tilney H, Thompson M, Smith J, Tekkis PP. The United Kingdom National Bowel Cancer Project – epidemiology and surgical risk in the elderly. *Eur J Cancer* 2007; **43**: 2285–94.
 - 181 Faiz O, Haji A, Bottle A, Clark SK, Darzi AW, Aylin P. Elective colonic surgery for cancer in the elderly: an investigation into postoperative mortality in English NHS hospitals between 1996 and 2007. *Colorectal Dis* 2011; **13**: 779–85.
 - 182 Faiz O, Warusavitarne J, Bottle A, Tekkis PP, Darzi AW, Kennedy RH. Laparoscopically assisted vs. open elective colonic and rectal resection: a comparison of outcomes in English National Health Service Trusts between 1996 and 2006. *Dis Colon Rectum* 2009; **52**: 1695–704.
 - 183 Copeland GP, Jones D, Walters M. POSSUM: a scoring system for surgical audit. *Br J Surg* 1991; **78**: 355–60.
 - 184 Richards CH, Leitch FE, Horgan PG, McMillan DC. A systematic review of POSSUM and its related models as predictors of post-operative mortality and morbidity in patients undergoing surgery for colorectal cancer. *J Gastrointest Surg* 2010; **14**: 1511–20.
 - 185 Mamidanna R, Burns EM, Bottle A, Aylin P, Stonell C, Hanna GB, *et al.* Reduced risk of medical morbidity and mortality in patients selected for laparoscopic colorectal resection in England: a population-based study. *Arch Surg* 2012; **147**: 219–27.
 - 186 Delaney CP, Brady K, Woconish D, Parmar SP, Champagne BJ. Towards optimizing perioperative colorectal care: outcomes for 1,000 consecutive laparoscopic colon procedures using enhanced recovery pathways. *Am J Surg* 2012; **203**: 353–5; discussion 5–6.
 - 187 Richards CH, Leitch EF, Anderson JH, McKee RF, McMillan DC, Horgan PG. The revised ACPGBI model is a simple and accurate predictor of operative mortality after potentially curative resection of colorectal cancer. *Ann Surg Oncol* 2011; **18**: 3680–5.
 - 188 Burns EM, Bottle A, Aylin P, Darzi A, Nicholls RJ, Faiz O. Variation in reoperation after colorectal surgery in England as an indicator of surgical performance: retrospective analysis of Hospital Episode Statistics. *BMJ* 2011; **343**: d4836.
 - 189 Ricciardi R, Roberts PL, Read TE, Marcello PW, Hall JF, Schoetz DJ. How often do patients return to the operating room after colorectal resections? *Colorectal Dis* 2012; **14**: 515–21.
 - 190 Emmertsen KJ, Laurberg S. Low anterior resection syndrome score: development and validation of a symptom-based scoring system for bowel dysfunction after low anterior resection for rectal cancer. *Ann Surg* 2012; **255**: 922–8.
 - 191 Kim PH, Song HY, Park JH, Kim JH, Na HK, Lee YJ. Safe and effective treatment of colorectal anastomotic stricture using a well-defined balloon dilation protocol. *J Vasc Interv Radiol* 2012; **23**: 675–80.
 - 192 Blomqvist L, Machado M, Rubio C, Gabrielsson N, Granqvist S, Goldman S, *et al.* Rectal tumour staging: MR imaging using pelvic phased-array and endorectal coils vs endoscopic ultrasonography. *Eur Radiol* 2000; **10**: 653–60.
 - 193 Brown G, Radcliffe AG, Newcombe RG, Dallimore NS, Bourne MW, Williams GT. Preoperative assessment of prognostic factors in rectal cancer using high-resolution magnetic resonance imaging. *Br J Surg* 2003a; **90**: 355–64.
 - 194 Fuchsjaeger MH, Maier AG, Schima W, Zebadin E, Herbst F, Mittlböck M, *et al.* Comparison of transrectal sonography and double-contrast MR imaging when staging rectal cancer. *AJR Am J Roentgenol* 2003; **181**: 421–7.
 - 195 Gagliardi G, Bayar S, Smith R, Salem RR. Preoperative staging of rectal cancer using magnetic resonance imaging with external phase-arrayed coils. *Arch Surg* 2002; **137**: 447–51.
 - 196 Giusti S, Bucciante P, Castagna M, Fruzzetti E, Fattori S, Castelluccio E, *et al.* Preoperative rectal cancer staging with phased-array MR. *Radiat Oncol* 2012; **7**: 29.
 - 197 Hadfield MB, Nicholson AA, MacDonald AW, Farouk R, Lee PW, Duthie GS, *et al.* Preoperative staging of rectal carcinoma by magnetic resonance imaging with a pelvic phased-array coil. *Br J Surg* 1997; **84**: 529–31.

- 198 Kim NK, Kim MJ, Park JK, Park SI, Min JS. Preoperative staging of rectal cancer with MRI: accuracy and clinical usefulness. *Ann Surg Oncol* 2000; **7**: 732–7.
- 199 Mathur P, Smith JJ, Ramsey C, Owen M, Thorpe A, Karim S, *et al.* Comparison of CT and MRI in the pre-operative staging of rectal adenocarcinoma and prediction of circumferential resection margin involvement by MRI. *Colorectal Dis* 2003; **5**: 396–401.
- 200 Videhult P, Smedh K, Lundin P, Kraaz W. Magnetic resonance imaging for preoperative staging of rectal cancer in clinical practice: high accuracy in predicting circumferential margin with clinical benefit. *Colorectal Dis* 2007; **9**: 412–9.
- 201 Beets-Tan RG, Beets GL, Vliegen RF, Kessels AG, Van Boven H, De Bruine A, *et al.* Accuracy of magnetic resonance imaging in prediction of tumour-free resection margin in rectal cancer surgery. *Lancet* 2001; **357**: 497–504.
- 202 Poon FW, McDonald A, Anderson JH, Duthie F, Rodger C, McCurrach G, *et al.* Accuracy of thin section magnetic resonance using phased-array pelvic coil in predicting the T-staging of rectal cancer. *Eur J Radiol* 2005; **53**: 256–62.
- 203 Kim JC, Cho YK, Kim SY, Park SK, Lee MG. Comparative study of three-dimensional and conventional endorectal ultrasonography used in rectal cancer staging. *Surg Endosc* 2002; **16**: 1280–5.
- 204 Akasu T, Kondo H, Moriya Y, Sugihara K, Gotoda T, Fujita S, *et al.* Endorectal ultrasonography and treatment of early stage rectal cancer. *World J Surg* 2000; **24**: 1061–8.
- 205 Ashraf S, Hompes R, Slater A, Lindsey I, Bach S, Mortensen NJ, *et al.* A critical appraisal of endorectal ultrasound and transanal endoscopic microsurgery and decision-making in early rectal cancer. *Colorectal Dis* 2012; **14**: 821–6.
- 206 Garcia-Aguilar J, Pollack J, Lee SH, Hernandez de Anda E, Mellgren A, Wong WD, *et al.* Accuracy of endorectal ultrasonography in preoperative staging of rectal tumors. *Dis Colon Rectum* 2002; **45**: 10–5.
- 207 Mackay SG, Pager CK, Joseph D, Stewart PJ, Solomon MJ. Assessment of the accuracy of transrectal ultrasonography in anorectal neoplasia. *Br J Surg* 2003; **90**: 346–50.
- 208 Marusch F, Koch A, Schmidt U, Zippel R, Kuhn R, Wolff S, *et al.* Routine use of transrectal ultrasound in rectal carcinoma: results of a prospective multicenter study. *Endoscopy* 2002; **34**: 385–90.
- 209 Sailer M, Leppert R, Kraemer M, Fuchs KH, Thiede A. The value of endorectal ultrasound in the assessment of adenomas, T1- and T2-carcinomas. *Int J Colorectal Dis* 1997; **12**: 214–9.
- 210 Massari M, De Simone M, Cioffi U, Rosso L, Chiarelli M, Gabrielli F. Value and limits of endorectal ultrasonography for preoperative staging of rectal carcinoma. *Surg Laparosc Endosc* 1998; **8**: 438–44.
- 211 Marusch F, Ptok H, Sahm M, Schmidt U, Ridwelski K, Gasting I, *et al.* Endorectal ultrasound in rectal carcinoma—do the literature results really correspond to the realities of routine clinical care? *Endoscopy* 2011; **43**: 425–31.
- 212 Chung HW, Chung JB, Park SW, Song SY, Kang JK, Park CI. Comparison of hydrocolonic sonography accuracy in preoperative staging between colon and rectal cancer. *World J Gastroenterol* 2004; **10**: 1157–61.
- 213 Hurlstone DP, Brown S, Cross SS, Shorthouse AJ, Sanders DS. High magnification chromoscopic colonoscopy or high frequency 20 MHz mini probe endoscopic ultrasound staging for early colorectal neoplasia: a comparative prospective analysis. *Gut* 2005; **54**: 1585–9.
- 214 Matsumoto T, Hizawa K, Esaki M, Kurahara K, Mizuno M, Hirakawa K, *et al.* Comparison of EUS and magnifying colonoscopy for assessment of small colorectal cancers. *Gastrointest Endosc* 2002; **56**: 354–60.
- 215 Tanabe R, Higaki S, Gondo T, Sakaida I. Preoperative evaluation of early colorectal cancer using an ultrasound mini probe. *Hepatogastroenterology* 2011; **59**: 1794–9.
- 216 Urban O, Kliment M, Fojtik P, Falt P, Orhalmi J, Vitek P, *et al.* High-frequency ultrasound probe sonography staging for colorectal neoplasia with superficial morphology: its utility and impact on patient management. *Surg Endosc* 2011; **25**: 3393–9.
- 217 Watanabe H, Miwa H, Terai T, Imai Y, Ogihara T, Sato N. Endoscopic ultrasonography for colorectal cancer using submucosal saline solution injection. *Gastrointest Endosc* 1997; **45**: 508–11.
- 218 Brown G, Richards CJ, Bourne MW, Newcombe RG, Radcliffe AG, Dallimore NS, *et al.* Morphologic predictors of lymph node status in rectal cancer with use of high-spatial-resolution MR imaging with histopathologic comparison. *Radiology* 2003b; **227**: 371–7.
- 219 Ferri M, Laghi A, Mingazzini P, Iafrate F, Meli L, Ricci F, *et al.* Pre-operative assessment of extramural invasion and sphincter involvement in rectal cancer by magnetic resonance imaging with phased-array coil. *Colorectal Dis* 2005; **7**: 387–93.
- 220 Matsuoka H, Nakamura A, Masaki T, Sugiyama M, Takahara T, Hachiya J, *et al.* Comparison between endorectal coil and pelvic phased-array coil magnetic resonance imaging in patients with anorectal tumor. *Am J Surg* 2003; **185**: 328–32.
- 221 Landmann RG, Wong WD, Hoepfl J, Shia J, Guillem JG, Temple LK, *et al.* Limitations of early rectal cancer nodal staging may explain failure after local excision. *Dis Colon Rectum* 2007; **50**: 1520–5.
- 222 Nesbakken A, Lovig T, Lunde OC, Nygaard K. Staging of rectal carcinoma with transrectal ultrasonography. *Scand J Surg* 2003; **92**: 125–9.
- 223 Palacios Fanlo M, Ramirez Rodriguez J, Aguilera Diago V, Arribas Del Amo D, Martinez Diez M, Lozano Mantecón R. Endoluminal ultrasonography for rectal tumors: efficacy, sources of error and limitations. *Rev Esp Enferm Dig* 2000; **92**: 222–31.
- 224 Hünerbein M, Handke T, Ulmer C, Schlag PM. Impact of miniprobe ultrasonography on planning of minimally invasive surgery for gastric and colonic tumors. *Surg Endosc* 2004; **18**: 601–5.